Research Article

Anaesthetic Management of Retrosternal Goiter with Tracheal Deviation in a Patient with Multiple Comorbidities: A Case Report

Dr. Harshini Kalidoss[1], Dr. Shruthi Vinothkumar[2]

[1]Postgraduate, Department of Anaesthesiology and critical care, Sree Balaji Medical College and Research Institute, No .7 CLC works road,Chrompet, Tamilnadu -600044, Bharath Institute of Higher Education and Research(BIHER), Email id: harshinikalidoss@gmail.com
[2]Senior resident, Department of Anaesthesiology and critical carem, Sree Balaji Medical College and Research Institute, No .7 CLC works road ,Chrompet,Tamilnadu -600044, Bharath Institute of Higher Education and Research(BIHER), Email id: drshruthidarshan@gmail.com
***Corresponding Author:** Dr. Shruthi Vinothkumar, drshruthidarshan@gmail.com

Abstract

Introduction: Retrosternal goiter poses significant challenges in airway management and surgical intervention due to the anatomical extension of the thyroid gland into the mediastinum. When complicated by multiple comorbidities and indeterminate cytology, a meticulously planned multidisciplinary approach is essential.
Case Presentation: We report a case of a 68-year-old female who presented with multiple episodes of giddiness and a history of a fall. An incidental finding of a right-sided goiter led to further evaluation. She had a significant medical history of diabetes mellitus, hypertension, coronary artery disease (CAD), and vestibular neuronitis. Imaging revealed a retrosternal extension of the right thyroid lobe up to the D4-D5 vertebral level, causing a mild tracheal shift to the left. Ultrasound neck demonstrated a multinodular goiter (TIRADS III), and fine-needle aspiration cytology (FNAC) indicated atypia of undetermined significance (Bethesda Category IV). Preoperative multidisciplinary evaluation included cardiology, pulmonology, and cardiothoracic vascular surgery (CTVS) clearances. The patient underwent an awake nasal Lateral fibreoptic intubation utilizing dexmedetomidine and a trans-tracheal block, followed by a total thyroidectomy under general anesthesia with a supplementary ultrasound-guided cervical plexus block. The intraoperative and postoperative periods were uneventful, and the patient was successfully extubated and shifted to the ICU for observation.
Conclusion: The successful management of this case highlights the importance of comprehensive preoperative airway assessment, multidisciplinary collaboration, and tailored anaesthetic techniques in patients with retrosternal goiter and complex medical profiles.

Introduction

Retrosternal goiter, defined as a thyroid gland extending below the thoracic inlet into the mediastinum, is a relatively common clinical entity encountered by endocrine and head and neck surgeons [1]. While many patients remain asymptomatic, the presence of a retrosternal component can lead to significant compressive symptoms involving the trachea, esophagus, and vascular structures [2]. Furthermore, the anatomical distortion poses a unique set of challenges for anesthesiologists, particularly regarding airway management, as these patients are at a higher risk of difficult ventilation, difficult intubation, and post-extubation airway compromise [3].

The coexistence of retrosternal goiter with systemic comorbidities such as coronary artery disease (CAD), diabetes mellitus (DM), and hypertension (HTN) further complicates the perioperative plan [4]. Additionally, the presence of indeterminate thyroid nodules on cytology necessitates definitive surgical management to rule out malignancy [5]. This case report details the clinical presentation, diagnostic workup, and comprehensive anaesthetic and surgical management of a 68-year-old female with a retrosternal goiter, tracheal deviation, and a history of multiple significant comorbidities.

Case Presentation

A 68-year-old female presented to our institution with complaints of multiple episodes of giddiness and a history of a fall at her residence. During her evaluation for the fall, a thyroid swelling was noted as an incidental finding. She was subsequently admitted for a comprehensive evaluation and surgical planning.

Her medical history was significant for type 2 diabetes mellitus and hypertension, both diagnosed 20 years prior, managed with oral hypoglycemic agents (Metformin 500 mg, Glimepiride 2 mg) and antihypertensives (Metoprolol 25 mg, Enalapril 2.5 mg). She was also a known case of coronary artery disease (CAD) for the past two years, managed medically with Ecosprin 150 mg, Clopidogrel 75 mg, and Atorvastatin 20 mg. She reported no prior history of angioplasty. She had been diagnosed with vestibular neuronitis one month prior to presentation, for which she was taking Vertin 16 mg, Flunarizine 10 mg, and Stemetil. Additional surgical history included a remote history of right lower motor neuron facial palsy 20 years ago (resolved with physiotherapy) and a dacryocystorhinostomy (DCR) with local anesthesia one year prior. There was no history of fever, cough, cold, or known drug allergies.

On general physical examination, the patient was conscious and oriented. Her vitals were stable: pulse rate 84/min, blood pressure 130/70 mmHg, and SpO2 98% on room air. Local examination of the neck revealed a 2 x 2 cm swelling on the right side. The lower border of the swelling was not palpable, and it did not move with the protrusion of the tongue (Fig 1). Pemberton's sign was negative, and the trachea appeared clinically central. Airway examination revealed a Mallampati Class III, adequate mouth opening (3 fingers), and a restricted neck. Buck teeth and artificial dentures were present. Bilateral air entry was equal on respiratory examination, and cardiovascular examination revealed S1S2 normal. Power and sensation were intact in all four limbs.

Investigations

Routine laboratory investigations were within normal limits, with hemoglobin 12.6 g/dL, platelets 345 x 10^3/µL, urea 19 mg/dL, and creatinine 0.57 mg/dL. Electrolytes were normal (Na 139 mEq/L, K 4.55 mEq/L). An electrocardiogram (ECG) was within normal limits. A comprehensive imaging and diagnostic workup was initiated. An ultrasound of the neckrevealed an enlarged thyroid with a heterogeneous echotexture. The right lobe measured 5.3 x 3.4 x 3.4 cm, the left lobe measured 5.8 x 3.5 x 2.5 cm, and the isthmus measured 5.2 mm. Multiple well-circumscribed hyperechoic solid nodules were noted, the largest measuring 2.0 x 1.8 cm in the right lobe, with internal cystic spaces and increased vascularity. The impression was multinodular goiter (TIRADS III) with underlying thyroiditis.

A multi-slice CT scan of the chest demonstrated the retrosternal extension of the right lobe of the thyroid with few specks of calcification extending to the level of the carina at the D4-D5 vertebral level, causing a mild tracheal shift to the left. A few prominent subcentimetric lymph nodes were noted in the pre-carinal and para-aortic regions. Atherosclerotic changes were observed in the descending aorta.

Fine-needle aspiration cytology (FNAC) of the thyroid nodule was performed, which yielded a Bethesda Category IV result (Atypia of Undetermined Significance). An echocardiogram showed a normal ejection fraction of 67%, mild aortic regurgitation, mild tricuspid regurgitation, and a small atrial septal defect (ASD) with a left-to-right shunt. The cardiologist recommended starting prophylactic antibiotics seven days prior to surgery. An MRI of the brain, performed for the history of falls, showed hyperintense foci in the bilateral frontoparietal region consistent with chronic small vessel ischemic changes, without any acute infarct.

Preoperative Preparation

Given the retrosternal extension, tracheal deviation, and the patient's multiple comorbidities, a multidisciplinary approach was adopted. Cardiothoracic vascular surgery (CTVS) and pulmonology opinions were obtained. The pulmonologist categorized the patient as moderate risk but noted that adequate cardiopulmonary monitoring would be sufficient. A video laryngoscopy examination (VLE) was performed preoperatively to visualize the vocal cords, which showed normal bilateral cord movements. Preoperatively, the patient’s baseline vital signs were meticulously recorded in multiple positions to assess for positional hemodynamic or respiratory compromise. In the supine position, her pulse rate was 84 bpm, blood pressure was 140/80 mmHg, and SpO2 was 90%. When placed in the lateral position, her pulse rate was 82 bpm, blood pressure was 140/90 mmHg, and SpO2 improved to 98%. Similarly, in the sitting position, her pulse rate remained at 82 bpm, blood pressure was 140/90 mmHg, and SpO2 was 97%. The notable drop in oxygen saturation to 90% in the supine position compared to the sitting and lateral positions suggested a degree of positional airway compression, likely secondary to the retrosternal goiter, which was a critical consideration for induction and airway management planning.The patient was classified as ASA III. Given the anticipated difficult airway due to retrosternal extension, restricted neck mobility, and Mallampati III, an awake fibreoptic intubation was planned.

Anesthetic and Surgical Management

On the day of surgery, the patient was shifted to the operating room. Baseline vitals were recorded, and standard ASA monitors were connected. The patient was premedicated with intravenous Dexmedetomidine 30 mcg. Following adequate topicalization, an awake nasal Lateral fibreoptic intubation was performed using a 6.5 mm flexometallic endotracheal tube with a "spray-as-you-go" technique. A trans-tracheal block was administered with 3 mL of 2% Lignocaine to facilitate the procedure. The tube was fixed at 26 cm after confirming equal bilateral air entry. Following induction, the patient was positioned with a head-up tilt to reduce venous congestion. An ultrasound-guided cervical plexus block (deep and superficial) was administered with 0.5% Bupivacaine and 20 mL of local anesthetic to provide perioperative analgesia.

The surgical team proceeded with a total thyroidectomy. Intraoperatively, the retrosternal extension was carefully dissected from the mediastinal structures. The total duration of the procedure was 3 hours. The total

blood loss was estimated at 350 mL, and the patient received 2300 mL of intravenous fluids. Urine output was maintained at 125 mL. During the procedure, the patient's vitals remained stable. The intraoperative period was uneventful, and the excised thyroid gland was sent for histopathological examination (Fig. 2 and 3).

Postoperative Course

At the end of the procedure, the patient was reversed with Inj. Sugammadex 200 mg. After achieving good respiratory effort, adequate tidal volume, and good power and tone, suctioning was performed, and an extubation was successfully carried out. Post-extubation, the patient demonstrated intact vocalization, an intact cough reflex, and good airway patency.

The patient was shifted to the Intensive Care Unit (ICU) for observation. Handover was given to the ICU consultant and the ICU anesthesiology team. Postoperative vitals were stable: PR 78/min, BP 140/90 mmHg, SpO2 100% on room air. A bedside chest X-ray (Fig. 4) confirmed the central position of the trachea, clear lung fields, and correct placement of lines. The patient was advised NPO for 6 hours, maintained on intravenous fluids, and prescribed adequate analgesia. Monitoring of vitals, urine output, and strict input/output charting were continued. Routine postoperative investigations, including CBC, RFT, and serum electrolytes, were ordered. The patient remained hemodynamically stable and was subsequently transferred to the ward on the following day.

Discussion

The management of a retrosternal goiter in a patient with multiple comorbidities requires a highly coordinated effort between anesthesiologists, surgeons, and physicians [6]. The primary anaesthetic challenge in this case was the anticipated difficult airway. The patient presented with multiple predictors of a difficult airway: a Mallampati Class III, restricted neck mobility, a retrosternal goiter causing tracheal deviation, and the presence of artificial dentures.

Awake fibreoptic intubation is widely considered the gold standard for managing anticipated difficult airways in patients with large neck masses [7]. By maintaining spontaneous ventilation, the anesthesiologist can secure the airway before the loss of muscle tone, which might otherwise lead to complete airway obstruction if the trachea is significantly compressed. The use of dexmedetomidine provided excellent sedation and anxiolysis without causing respiratory depression, which is crucial during awake intubations [8]. The trans-tracheal block with lignocaine further anesthetized the airway, suppressing the cough reflex during the passage of the tube.

The presence of coronary artery disease and diabetes mellitus necessitated careful perioperative hemodynamic monitoring. The use of a cervical plexus block provided excellent regional analgesia, reducing the need for systemic opioids and thereby minimizing the risk of postoperative respiratory depression [9]. Furthermore, maintaining normotension and avoiding tachycardia were critical in preventing myocardial ischemia in this patient with CAD.

The FNAC result of Bethesda Category IV (Atypia of Undetermined Significance) carries a risk of malignancy of approximately 10-30% [10]. Therefore, a total thyroidectomy was justified not only for symptomatic relief (compressive symptoms and tracheal deviation) but also for definitive diagnostic and therapeutic purposes. The retrosternal extension up to the D4-D5 level required careful dissection to avoid injury to the recurrent laryngeal nerves and parathyroid glands, which is a known risk in thyroid surgeries [11].The multidisciplinary approach involving the cardiologist, pulmonologist, and CTVS team ensured that all comorbidities were optimized before surgery. The prophylactic administration of antibiotics, as advised by the cardiologist due to the small ASD, highlights the importance of individualized patient care [12].However, the successful outcome in this high-risk patient underscores the value of meticulous preoperative planning and the application of advanced airway management techniques.

Conclusion

The successful management of a patient with a retrosternal goiter, tracheal deviation, and multiple comorbidities requires a multidisciplinary approach. Awake fibreoptic intubation is a safe and effective technique for securing a difficult airway in such patients. The combination of regional anesthesia (cervical plexus block) and careful perioperative monitoring helps ensure a smooth intraoperative and postoperative course.

References

1. Katlic MR, Wang CA, Grillo HC. Substernal goiter. Ann Thorac Surg. 1985;39(4):391-399.
2. Rios A, Rodriguez JM, Balsalobre MD, Tebar FJ, Parrilla P. The value of various definitions of a retrosternal goiter for predicting the need for sternotomy. Surgery. 2010;147(1):99-105.

3. Dempsey GA, Snell JA, Coathup R, Jones TM. Anaesthesia for massive retrosternal thyroidectomy in a tertiary referral centre. Br J Anaesth. 2013;111(4):594-599.
4. Nihalani S, Mehta S, Shah R. Anesthetic management of a patient with retrosternal goiter and multiple comorbidities: A case report. Indian J Anaesth. 2018;62(5):388-390.
5. Cibas ES, Ali SZ. The Bethesda System for Reporting Thyroid Cytopathology. Thyroid. 2009;19(11):1159-1165.
6. Pieracci FM, Fahey TJ 3rd. Substernal thyroidectomy is associated with increased morbidity and mortality as compared with conventional cervical thyroidectomy. J Am Coll Surg. 2007;205(1):1-7.
7. Apfelbaum JL, Hagberg CA, Caplan RA, et al. Practice guidelines for management of the difficult airway: an updated report by the American Society of Anesthesiologists Task Force on Management of the Difficult Airway. Anesthesiology. 2013;118(2):251-270.
8. Weerink MA, Struys MM, Hannivoort LN, Barends CR, Absalom AR, Colin P. Clinical pharmacokinetics and pharmacodynamics of dexmedetomidine. Clin Pharmacokinet. 2017;56(8):893-913.
9. Apan A, Cekic B, Kose EA, et al. Comparison of the efficacy of ultrasound-guided superficial cervical plexus block with local infiltration anesthesia for thyroid surgery. J Clin Anesth. 2014;26(8):650-655.
10. Bongiovanni M, Spitale A, Faquin WC, Mazzucchelli L, Baloch ZW. The Bethesda System for Reporting Thyroid Cytopathology: a meta-analysis. Acta Cytol. 2012;56(4):333-339.
11. Efremidou EI, Papageorgiou MS, Liratzopoulos N, Manolas KJ. The efficacy and safety of total thyroidectomy in the management of benign thyroid disease: a review of 932 cases. Can J Surg. 2009;52(1):39-44.
12. Wilson W, Taubert KA, Gewitz M, et al. Prevention of infective endocarditis: guidelines from the American Heart Association. Circulation. 2007;116(15):1736-1754.

Figure Legends

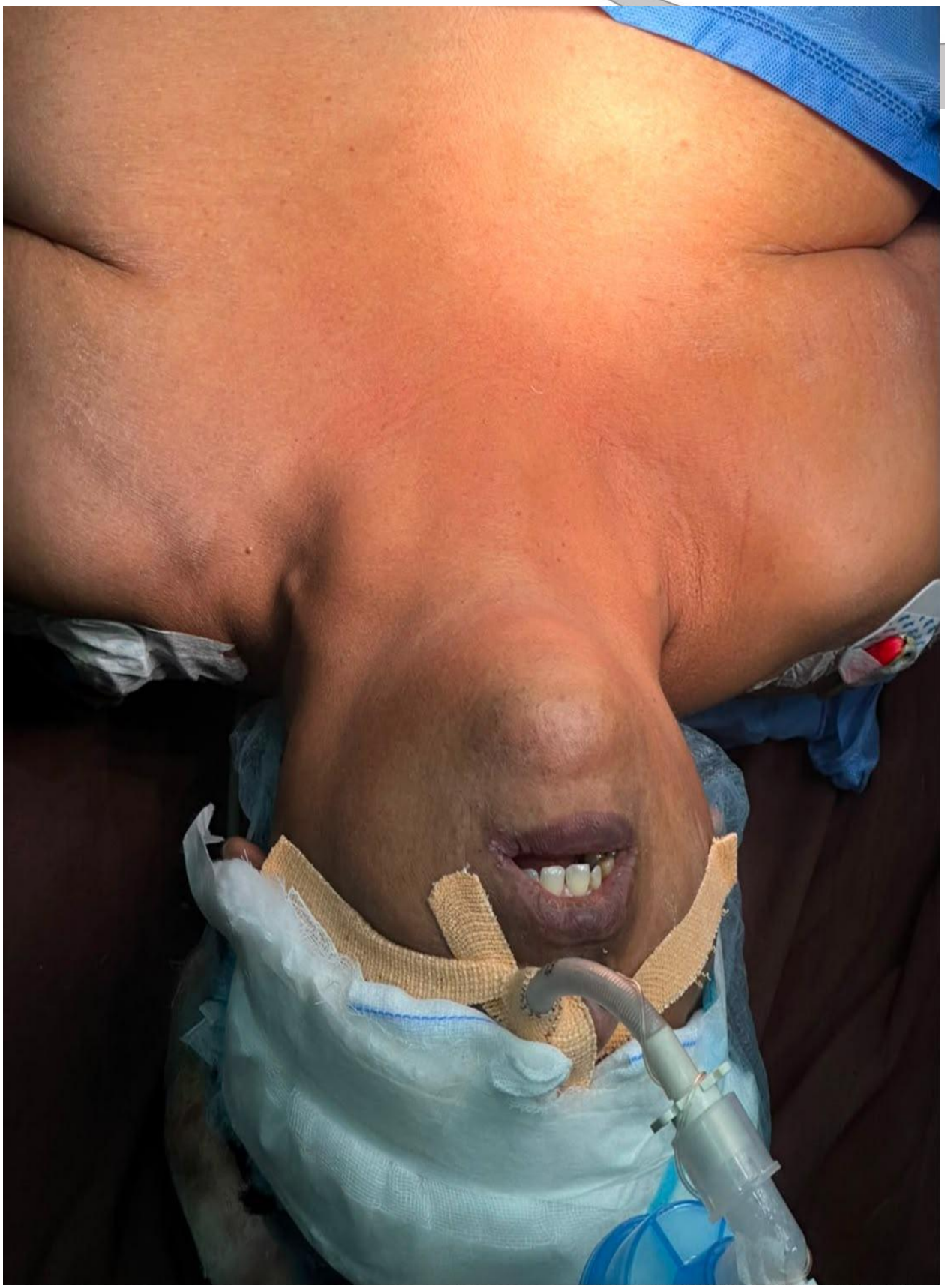

Figure 1: Gross Image of the neck of the patient

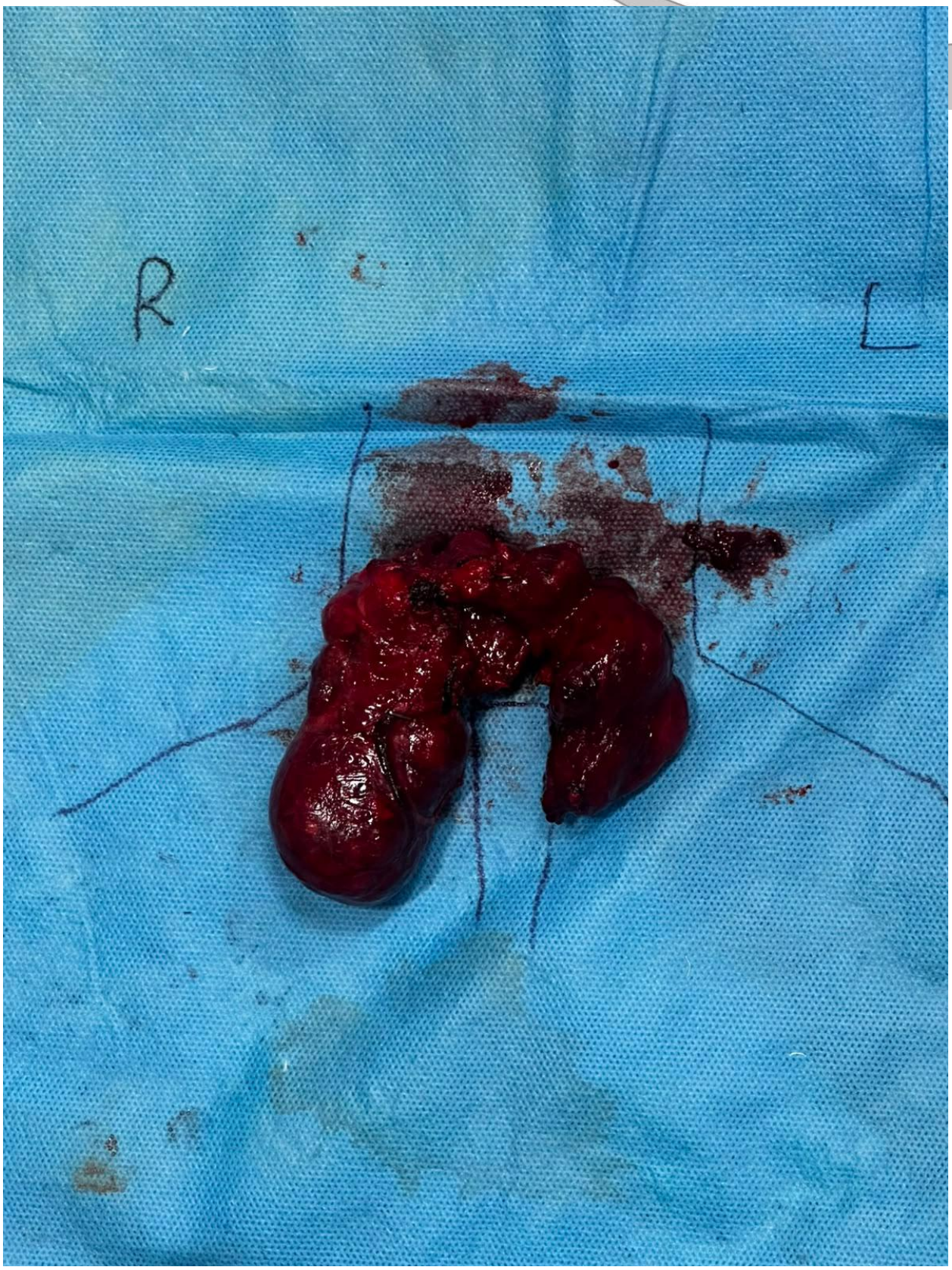

Figure 2: Gross specimen of the excised thyroid gland showing multinodular enlargement.

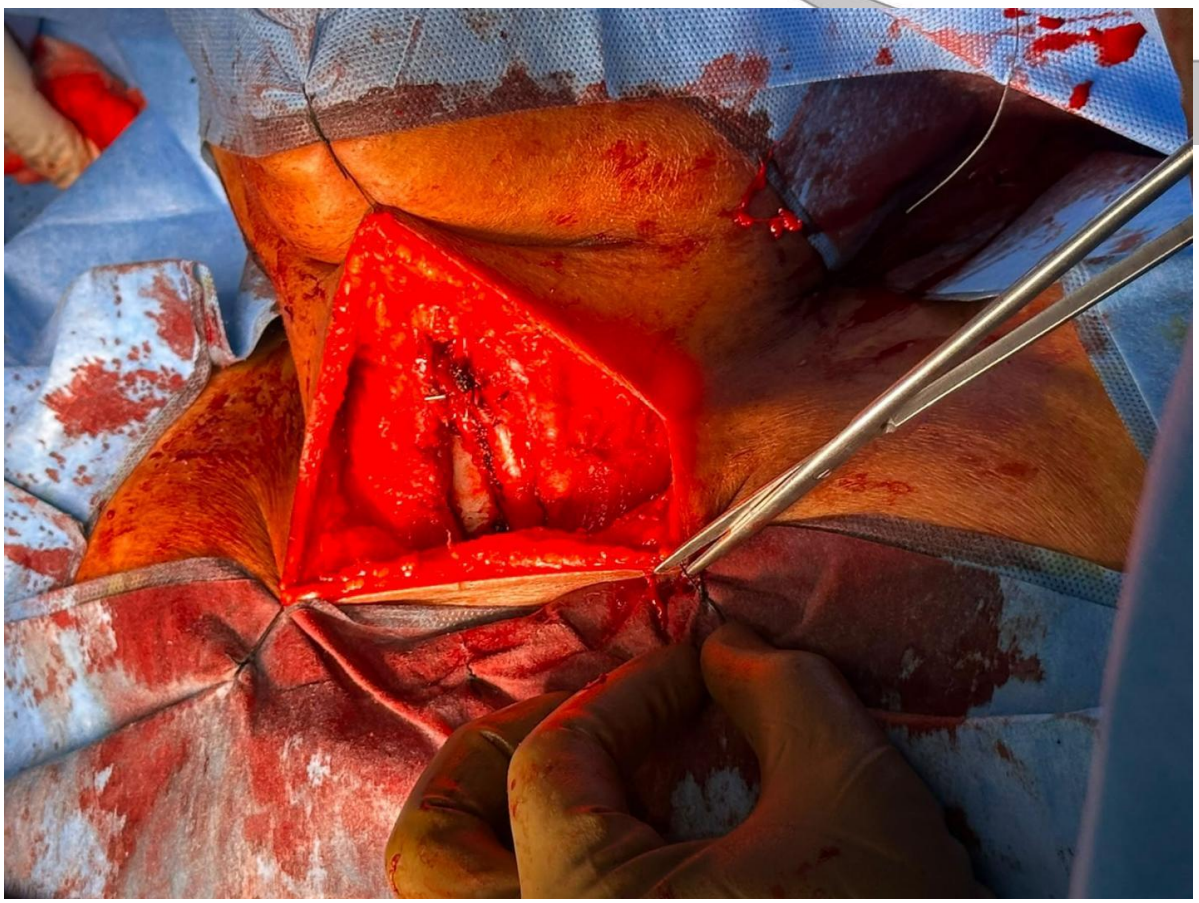

Figure 3:Intraoperative photograph showing the surgical field during total thyroidectomy.

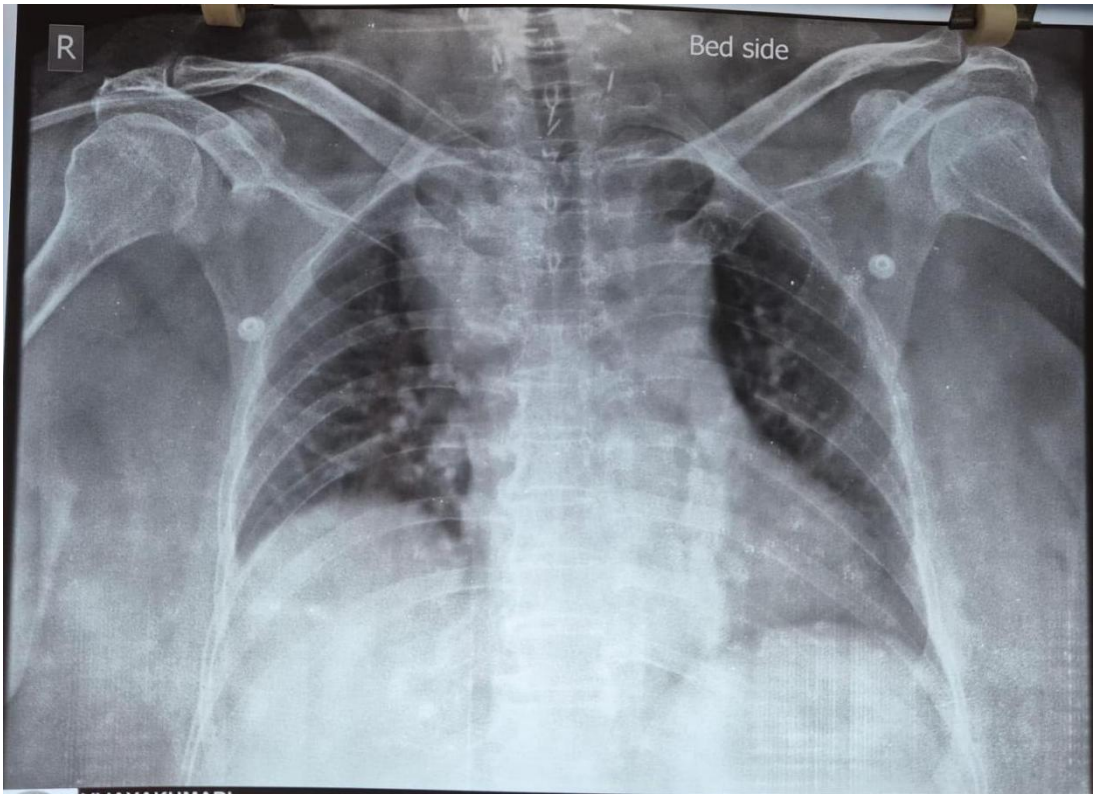

Figure 4: Postoperative bedside chest X-ray showing clear lung fields and a centrally positioned endotracheal tube.