Research Article

Secondary Posterior Canal Benign Paroxysmal Positional Vertigo Following Vestibular Neuritis: A Comprehensive Audio-Vestibular Case Report

Sushmita Nemagoud[1], Somaraj Odeyar[2], T. Suresh [3], Dr.A. Srividya[4]

[1,2,3,4] BVVS Institute of Speech and Hearing, Department of Audiology and Speech Language Pathology, S. Nijalingappa Medical College & HSK Hospital, Bagalkote, Karnataka, India
somarajodeyar@gmail.com, the.srividya@gmail.com, sushmithanemgoud@gmail.com, suresh.slp.audio@gmail.com

Abstract

Vestibular neuritis is an acute peripheral vestibulopathy characterized by vertigo, nausea, and imbalance, and although it is usually self limiting, approximately 10–15% of patients subsequently develop secondary benign paroxysmal positional vertigo. The coexistence of superior vestibular neuritis with secondary horizontal canal BPPV is rare and presents a diagnostic challenge. In this report, a retrospective single case study was conducted on a 26 year old female who presented with acute vertigo and was evaluated using pure tone and speech audiometry, Dix–Hallpike and log roll maneuvers, cervical and ocular Vestibular Evoked Myogenic Potentials, the Dizziness Handicap Inventory, and MRI. Rehabilitation consisted of canalith repositioning with the Epley maneuver, gaze stabilization, and daily Brandt–Daroff exercises. Initial findings revealed minimal bilateral hearing loss with preserved speech recognition, and vestibular testing confirmed left superior vestibular neuritis with absent left oVEMP and preserved cVEMP, along with coexisting horizontal canal BPPV. At three week follow up, reassessment demonstrated marked improvement in dizziness, enhanced postural stability, recovery of oVEMP responses, and reduced DHI scores. This case underscores the importance of comprehensive vestibular testing to identify secondary canal involvement following vestibular neuritis and demonstrates that targeted rehabilitation combining canalith repositioning and habituation exercises can effectively resolve symptoms, facilitate compensation, and improve overall quality of life.

Keywords: Vestibular neuritis, Benign Paroxysmal Positional Vertigo, Vestibular rehabilitation, Dizziness Handicap Inventory, VEMP, Case report.

1. Introduction

Vertigo is one of the most common clinical complaints in otolaryngology, neurology, and audiological practice (1). Vestibular neuritis (VN) represents a primary cause of acute peripheral vestibular syndrome, characterized by the sudden onset of severe, prolonged rotational vertigo, nausea, vomiting, postural instability, and spontaneous nystagmus, without associated auditory or central neurological symptoms (1).

VN is a self-limiting condition; management involves ruling out central or posterior circulation disorders/brainstem strokes followed by medical treatment during its acute phase. Patients frequently experience residual dizziness and sensitivity to visual moving objects for weeks or months. During recovery, displaced otoconia from the damaged utricle may enter the semicircular canals, resulting in secondary Benign Paroxysmal Positional Vertigo (BPPV) (2). Secondary BPPV has been reported to affect approximately 10–15% of patients following vestibular neuritis, with the posterior semicircular canal being the most common site of canalithiasis (3).Accurate clinical differentiation between persistent VN and secondary BPPV is critical because their management strategies differ (2). VN requires symptomatic suppressants and vestibular rehabilitation [4], whereas BPPV is treated through canalith repositioning maneuvers (5). The coexistence of superior vestibular neuritis and secondary horizontal canal BPPV is relatively underreported, particularly in peripheral clinical settings in India. Detailed documentation of these cases is essential to clarify diagnostic protocols, lesion localization, and rehabilitative outcomes.

The overlapping clinical presentation of acute vestibular neuritis and secondary horizontal canal BPPV poses diagnostic and therapeutic challenges for clinicians. Identifying which of the two is the primary cause of subjective symptoms is challenging. Such cases are rarely documented, particularly in tertiary healthcare centers in North Karnataka. Neuroimaging findings (such as MRI) are typically normal in peripheral vestibular disorders and are helpful in differential diagnosis of posterior circulation abnormalities. A comprehensive audiological and vestibular evaluation is

crucial to achieve a precise site-of-lesion diagnosis (6,7). Documenting this case adds to the large body of literature fostering a deeper understanding of peripheral vestibular pathophysiology, mechanisms of compensation, and the efficacy of targeted rehabilitation protocols.

2. Case Presentation

A 26-year-old female presented to our department with a chief complaint of sudden-onset, severe, spinning vertigo accompanied by profound postural instability, nausea, and vomiting of four days' duration. The vertigo was significantly exacerbated by head movements, such as rolling over in bed, looking up, or bending forward. The patient provided written informed consent for participation and the clinical publication of her data. specific signs of central neurological deficits, orthopedic limitations, or cognitive impairment—were not presented / not applicable.

2.1 Diagnostic Timeline and Assessment Protocol

At the initial presentation, a comprehensive diagnostic evaluation was performed. Case history was obtained with detailed logging of symptom onset, course, triggers, and associated audio vestibular or neurological symptoms. Audiological evaluation included otoscopy, pure tone audiometry across 250–8000 Hz, and speech audiometry with measurement of the Speech Recognition Threshold (SRT) and Speech Discrimination Scores (SDS). Bedside vestibular evaluation comprised tandem gait, smooth pursuit, gaze testing, and the Dix–Hallpike maneuver. Objective vestibular evaluation was carried out using cervical and ocular vestibular evoked myogenic potentials (cVEMP and oVEMP). Neuroimaging involved review of brain and internal auditory canal Magnetic Resonance Imaging (MRI) to rule out central pathology. In addition, the Dizziness Handicap Inventory (DHI) was administered as a subjective handicap measure. Following 21 days of structured vestibular rehabilitation, a comprehensive post intervention assessment was conducted, repeating all clinical and objective tests to monitor recovery. At initial evaluation, otoscopic examination revealed bilaterally normal tympanic membranes. Pure-tone audiometry demonstrated bilateral minimal hearing loss with slight threshold elevations at lower frequencies. Right ear air-conduction thresholds ranged from 10 to 20 dB HL (PTA: 17.5 dB HL), and left ear thresholds ranged from 10 to 30 dB HL (PTA: 20 dB HL). Speech audiometry revealed excellent speech-recognition capabilities bilaterally, with an SRT of 15 dB HL and an SDS of 100% in both ears. The most comfortable level (MCL) was 60 dB HL bilaterally, and the uncomfortable loudness level (UCL) was 90 dB HL bilaterally.

Follow-up audiological evaluation at three weeks showed stable thresholds, identical to the initial assessment, confirming the absence of cochlear involvement.

2.2 Subjective and Bedside Vestibular Findings

Table 1: The subjective and bedside vestibular findings from initial and follow-up evaluations.

Test	Initial Evaluation (Pre-Intervention)	Follow-up Evaluation (Post-Intervention)	Clinical Interpretation
Tandem Gait Test	Significant postural sway towards the left side (eyes closed). Sway increased to loss of postural stability while standing on foam surface.	Stable gait, no sway observed.(eyes closed). Mild sway while on foam surface (eyes closed)	Resolution of acute vestibular disorder and setting in central compensation/ restoration of postural control.
Smooth Pursuit Test	Normal tracking to the right; abnormal, saccadic eye movements tracking to the left.	Normal, smooth tracking bilaterally.	Recovery of oculomotor control and gaze stability.
Gaze Test	Persistent right-beating nystagmus on rightward gaze; no nystagmus on leftward gaze.	No gaze-evoked nystagmus in any direction.	Normalization of tonic vestibular symmetry (Alexander's Law).
Dix–Hallpike Test/ Barbeque roll Maneuvere	Left side down: Elicited strong upbeating/torsional nystagmus beating towards the left ear. Nystagmus fatigued with repeated testing. Followed by Horizontal nystagmus on repeat testing after EPpley and on Barbeque roll test	No nystagmus or vertigo elicited on both Maneuvere bilaterally.	repositioning of left Horizontal canal otoconia and resolve of symptoms due to BPPV.

Note: The initial bedside findings are characteristic of an acute left-sided peripheral vestibular deficit (left-ward sway, right-beating nystagmus conforming to Alexander's Law) complicated by secondary left posterior canal BPPV.

The vestibular evoked myogenic potential (VEMP) findings provided critical physiological data for lesion localization.

Cervical VEMP (cVEMP) responses were elicited bilaterally at the initial evaluation, demonstrating intact saccular and inferior vestibular nerve pathways. Specifically, the right ear showed a P1 latency of 13.60 ms and an N1 latency of 22.0 ms, while the left ear showed a P1 latency of 15.60 ms and an N1 latency of 23.0 ms (fig 1). At follow up, the right ear demonstrated a shortened P1 latency of 6.20 ms and N1 latency of 13.80 ms, whereas the left ear showed a P1 latency of 16.20 ms and an N1 latency of 25.80 ms (fig 2).

Ocular VEMP (oVEMP) responses were used to evaluate utricular and superior vestibular nerve pathways. At the initial assessment, robust N1–P1 waves were elicited in the right ear, while responses were completely absent in the left (affected) ear, confirming left superior vestibular nerve dysfunction (fig 3). At follow up, oVEMP responses emerged and normalized bilaterally, demonstrating functional recovery of the left superior vestibular pathway. The right ear showed a P1 latency of 16 ms and an N1 latency of 11 ms, while the left ear showed a P1 latency of 19 ms and an N1 latency of 8 ms (fig 4).

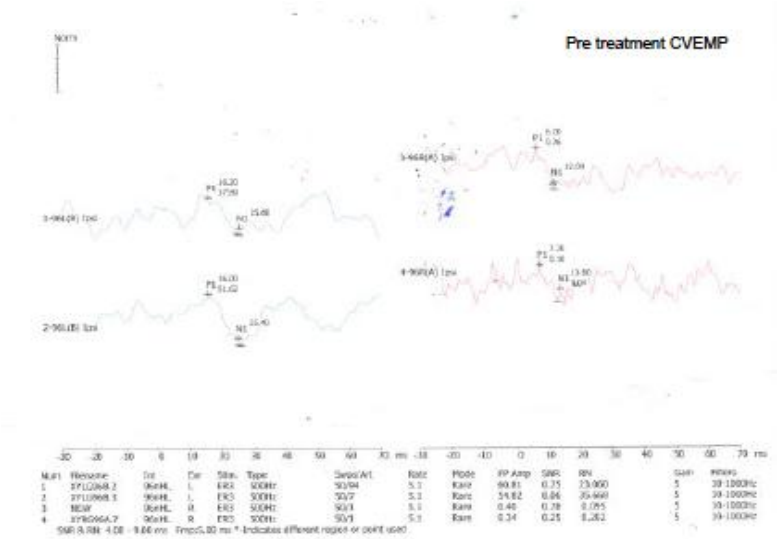

Figure 1: Pretreatment cervical VEMP (c VEMP) waveform demonstrating saccular and inferior vestibular nerve activity before management.

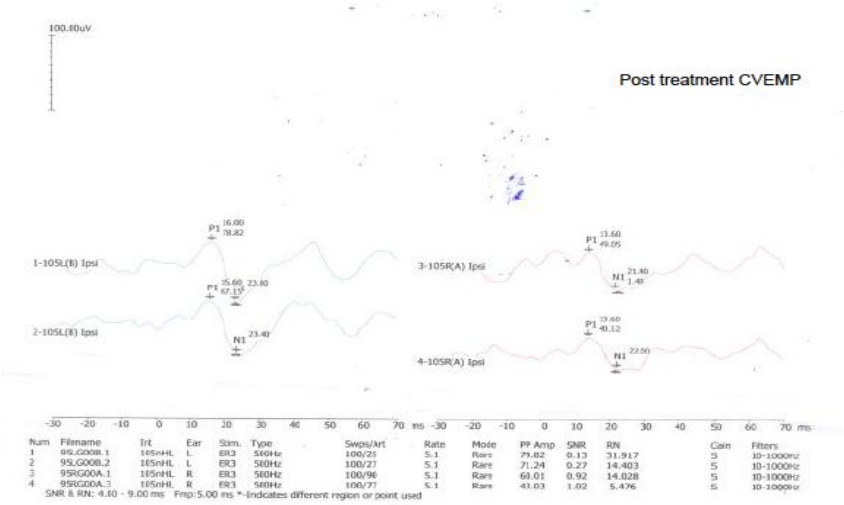

Figure 2: Posttreatment cervical VEMP (c VEMP) waveform demonstrating saccular and inferior vestibular nerve function following intervention.

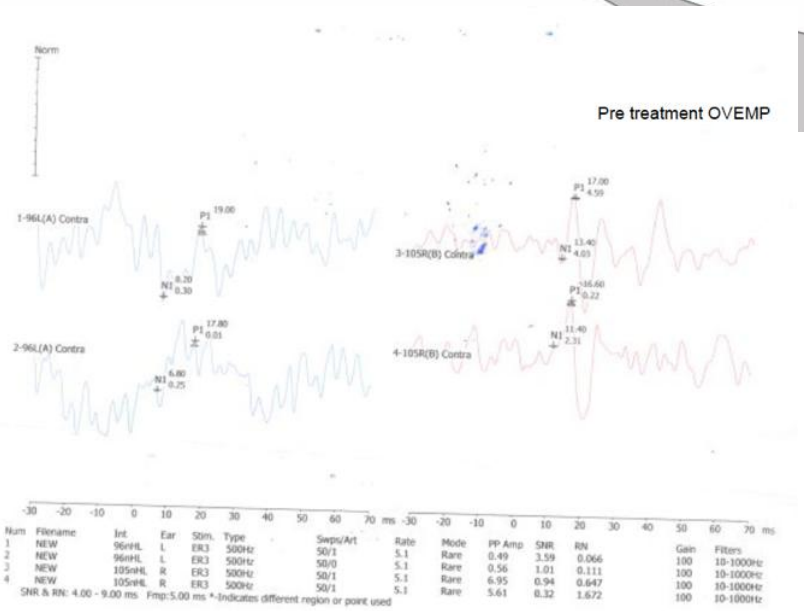

Figure 3: Pretreatment ocular VEMP (o VEMP) waveform illustrating utricular and superior vestibular nerve activity after treatment.

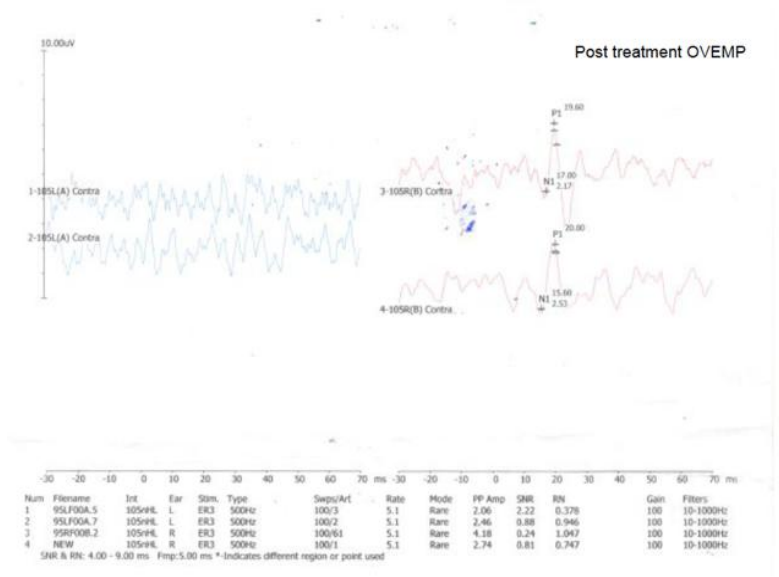

Figure 4: Posttreatment ocular VEMP (o VEMP) waveform illustrating utricular and superior vestibular nerve activity after treatment.

MRI findings were completely normal, ruling out central, vascular, or space-occupying lesions.

The therapeutic regimen spanned 21 days. On the day of evaluation, a clinician guided Epley maneuver was performed to clear the left posterior canal otoconia. Structured vestibular rehabilitation therapy was then initiated, consisting of daily gaze stabilization exercises using x1 and x2 viewing paradigms, along with habituation training. In addition, the patient was prescribed a home exercise program comprising Brandt–Daroff exercises to be performed three times daily for five consecutive days.Reassessment after three weeks revealed complete symptomatic resolution. The patient reported no episodes of positional or motion-induced vertigo. During the three week period the subject mainly reported dizziness when observing fast moving objects, or while moving head too quickly. She had no difficulty reported in picking objects bending down or looking down while climbing down the stairs. These symptoms reduced over the period of time. Post-rehabilitation DHI scores demonstrated a significant reduction, reflecting a path to recovery.

Bedside testing showed a normal tandem gait, symmetric smooth pursuit, absent gaze nystagmus, and a negative Dix–Hallpike test. Objectively, oVEMP responses changed from absent at initial test to present in the left ear during follow up test, indicating neural recovery alongside clinical compensation.

3. Discussion

Vestibular neuritis is an acute, unilateral peripheral vestibular disease, typically involving the superior branch of the vestibular nerve, which does not involve the cochlear nerve and inferior vestibular branch (1). This explains why our patient presented with normal speech discrimination and preserved hearing.

The primary clinical focus of this case is the pathophysiological relationship between left superior vestibular neuritis and secondary left posterior canal BPPV. During the acute inflammatory phase of SVN, the utricular macula undergoes degenerative changes, facilitating the dislodgement of calcium carbonate crystals (otoconia) (3). Because of gravity and the anatomical orientation of the semicircular canals, these free-floating otoconia gravitate most easily into the posterior semicircular canal [2]. The mechanical irritation of these crystals during head movement triggers the classic brief, positional vertigo episodes of BPPV, which superimpose on the continuous, motion-provoked dizziness of recovering VN (6).

Our clinical battery successfully localized the lesion. The leftward postural sway, abnormal leftward smooth pursuit, and right-beating gaze nystagmus (away from the side of lesion) clinically pointed to left-sided vestibular hypofunction (1). The diagnosis of superior vestibular branch involvement (SVN) was objectively supported by oVEMP and cVEMP patterns (7). Because the superior vestibular nerve innervates the utricle and lateral/superior semicircular canals, SVN typically results in an absent oVEMP on the affected side. Conversely, because the inferior vestibular nerve innervates the saccule and posterior semicircular canal, the cVEMP remains preserved. This exact “absent oVEMP, preserved cVEMP” pattern was observed in our patient’s left ear, confirming a Left Superior Vestibular Neuritis.

Importantly, the positive left-sided Dix–Hallpike test revealed coexisting left posterior canal BPPV. This demonstrates that although the inferior vestibular nerve (which innervates the posterior canal) was spared by the neuritis, the posterior canal itself was mechanically compromised by displaced utricular otoconia. The successful resolution of positional nystagmus following canalith repositioning maneuvers (5), combined with the normalization of gait and oculomotor tests after gaze-stabilization and Brandt–Daroff exercises (8), highlights the value of combining repositioning maneuvers with continued supervised vestibular rehabilitation (4,9).

Furthermore, the post-rehabilitation return of left oVEMP responses is consistent with the pathophysiology of vestibular neuritis and recovery, where inflammation reduction over time improves neural functioning (7). Vestibular rehabilitation helps in central compensation (4,8).

4. Conclusions

This case highlights the clinical importance of a comprehensive bedside and objective vestibular test battery in patients presenting with acute-onset vertigo. The combination of Left Superior Vestibular Neuritis and secondary Left Posterior Canal BPPV along with Left horizontal canal BPPV presents overlapping symptoms that can easily lead to incomplete treatment if not systematically checked and treated. Using cVEMP and oVEMP alongside positional testing is highly effective for precise site-of-lesion diagnosis. Clinicians should remain vigilant for secondary BPPV in patients recovering from vestibular neuritis, managing them with a dual approach of canalith repositioning and structured vestibular exercises to ensure complete functional recovery and a high quality of life.

References

1. Strupp M, Brandt T. Vestibular neuritis. Semin Neurol. 2009;29(5):509–519.
2. Kim JS, Zee DS. Benign paroxysmal positional vertigo. N Engl J Med. 2014;370(12):1138–1147.
3. Türk B, Akpinar M, Kaya KS, Korkut AY, Turgut S. Benign paroxysmal positional vertigo secondary to vestibular neuritis. Otolaryngol Head Neck Surg. 2021;100(7):656–662.
4. Jacobson GP, Newman CW. The development of the Dizziness Handicap Inventory. Arch Otolaryngol Head Neck Surg. 1990;116(4):424–427.

5. Rosengren SM, Welgampola MS, Colebatch JG. Vestibular evoked myogenic potentials: past, present and future. Clin Neurophysiol. 2010;121(5):636–651.
6. Furman JM, Cass SP. Benign paroxysmal positional vertigo. N Engl J Med. 1999;341(21):1590–1596.
7. Bhattacharyya N, et al. Clinical practice guideline: benign paroxysmal positional vertigo (update). Otolaryngol Head Neck Surg. 2017;156–S47.
8. Brandt T, Daroff RB. Physical therapy for benign paroxysmal positional vertigo. Arch Otolaryngol. 1980;106(8):484–485.
9. Herdman SJ, Hall CD, Maloney B, et al. Variables associated with outcome in patients with vestibular hypofunction. J Vestib Res. 2015;25:185–194.