Research Article

Evaluating the Role of Cd44 in Oral Squamous Cell Carcinoma (Oscc)

Ketki Ghanekar[1], Archana Buch[2], Vinayak Bawage[3], Charusheela Gore[4], Shirish Sahebrao Chandanwale[5]
Department of Pathology, Dr. D. Y. Patil Medical College, Hospital and Research Centre, Pimpri, Pune, Maharashtra 411018, India.

Author ORCID IDs
1. Ketki Ghanekar (Senior Resident): ORCID: 0009-0004-8499-3181
2. Archana Buch (Professor): ORCID: 0000-0002-8251-1941
3. Vinayak Bawage (Student, MBBS): ORCID: 0009-0007-9451-9725
4. Charusheela Gore (Head of department pathology): ORCID: 0000-0002-3158-485X
5. Shirish Sahebrao Chandanwale (Professor): ORCID: 0000-0002-7854-4564

Corresponding author: Dr. Archana Buch
Department of Pathology, Dr. D. Y. Patil Medical College, Hospital and Research Centre, Pimpri, Pune, Maharashtra 411018, India.

Abstract

Background: CD44 is a cancer stem cell–associated marker implicated in oral squamous cell carcinoma (OSCC), but its clinicopathological associations remain inconsistent. Objectives: To assess CD44 immunoexpression in OSCC and its associations with histological grade, pathological tumour stage, nodal status, and worst pattern of invasion (WPOI). Methods: This cross-sectional study included 100 surgically resected OSCC specimens. CD44 immunohistochemistry was assessed in the tumour centre and invasive front, and overall expression was evaluated across tumour sections. Associations were analysed using the chi-square or Fisher's exact test. Results: Overall CD44 expression was associated with histological grade ($\chi^2 = 13.93$, $p = 0.001$), pathological tumour stage ($\chi^2 = 18.11$, $p < 0.001$), and WPOI ($\chi^2 = 14.64$, $p = 0.006$), but not nodal status ($p = 0.196$). Strong membranous CD44 staining at the invasive front was observed in all 100 cases. Conclusions: Overall CD44 expression showed associations with selected histopathological parameters, whereas uniformly strong invasive-front staining could not distinguish clinicopathological subgroups. Studies incorporating clinical outcomes are needed to clarify its prognostic utility.

Keywords: Oral squamous cell carcinoma; CD44; immunohistochemistry; cancer stem cells; prognosis

1. Introduction

OSCC is the most common malignancy of the oral cavity, accounting for more than 90% of all oral cancers. It remains a major public health problem worldwide, particularly in developing countries such as India, where tobacco chewing, smoking, alcohol consumption, and betel quid use are highly prevalent. According to GLOBOCAN 2022 estimates, cancers of the lip and oral cavity constitute a significant proportion of cancer-related morbidity and mortality globally, with an increasing disease burden anticipated in the coming decades. [1,2]

Despite advances in surgical techniques, radiotherapy, chemotherapy, and targeted therapies, the overall survival rate of patients with OSCC has shown only modest improvement over the past several decades. This is largely attributable to local recurrence, regional lymph node metastasis, treatment resistance, and tumour heterogeneity. Conventional prognostic parameters such as tumour size, nodal status, histological grade, and TNM stage, although useful, do not always accurately predict tumour behaviour. Therefore, identification of reliable molecular biomarkers capable of predicting tumour aggressiveness and prognosis remains an area of active research. [2,3]

Cancer stem cells (CSCs) constitute a small subpopulation of tumour cells possessing self-renewal, differentiation, and tumour-initiating capacities. Increasing evidence suggests that CSCs contribute to tumour progression, invasion, metastasis, therapeutic resistance, and disease recurrence in OSCC. Among various CSC-associated markers, CD44 has emerged as one of the most extensively investigated molecules in head and neck malignancies. [4,5]

CD44 is a transmembrane glycoprotein that functions as the principal receptor for hyaluronic acid and is involved in multiple biological processes, including cell adhesion, proliferation, migration, angiogenesis, and lymphocyte activation. Through its interaction with the extracellular matrix and cytoskeletal proteins, CD44 facilitates tumour cell motility and invasion. Aberrant expression of CD44 has been implicated in tumour progression and poor clinical outcomes in several malignancies, including OSCC. [5,6]

Previous studies have demonstrated variable associations between CD44 expression and clinicopathological parameters in OSCC. While some investigators have reported significant correlations between increased CD44 expression and poor

differentiation, tumour progression, lymph node metastasis, and adverse prognosis, others have observed inconsistent or conflicting results. [6,7] Furthermore, limited studies have evaluated the relationship between CD44 expression and established prognostic indicators such as the worst pattern of invasion (WPOI), tumour size, and nodal status, particularly in the Indian population. [8,9]

Given these inconsistencies and the paucity of regional data, the present study was undertaken to evaluate CD44 immunoexpression in OSCC and to correlate its expression with established prognostic parameters including histological grade, tumour size, nodal status, TNM stage, and worst pattern of invasion.

2. Materials and Methods

Study design and setting

This cross-sectional observational study was conducted at a tertiary-care academic pathology department in Pune, Maharashtra, India, over a period of 11 years and 6 months from January 2015 to June 2026. The study protocol was approved by the Institutional Ethics Committee (approval number withheld for blinded review) and written informed consent was obtained from all participants prior to enrolment.

Sample size

A sample size of 97 was calculated in WinPepi using an assumed CD44 expression frequency of 49%, a 95% confidence level, and an acceptable difference of 19%. One hundred eligible cases were included. The underlying assumptions and calculation require confirmation against the original study records.

Participants

A total of 100 consecutive patients with histopathologically confirmed OSCC who underwent surgical resection during the study period were included.

Inclusion criteria

- Histopathologically confirmed cases of primary OSCC.
- Surgical specimens including mandibulectomy, maxillectomy, glossectomy and palatectomy specimens.
- Cases with adequate tumour tissue available for histopathological evaluation and immunohistochemistry.

Exclusion criteria

- Recurrent or secondary OSCC.
- Cases receiving neoadjuvant chemotherapy and/or radiotherapy prior to surgery.
- Punch and wedge biopsy specimens.
- Specimens with inadequate tissue for immunohistochemical analysis.

Variables and data collection

Clinicodemographic details including age, sex, anatomical site, smoking history, tobacco chewing habits and other relevant clinical information were retrieved from medical records.

Histopathological parameters evaluated included histological grade, tumour size, tumour-node-metastasis (TNM) stage, depth of invasion (DOI), worst pattern of invasion (WPOI), perineural invasion (PNI), lymphovascular invasion (LVI), and lymph node metastasis.

Histological grading was performed according to the World Health Organization (WHO) Classification of Head and Neck Tumours.[10] Tumour staging was carried out according to the American Joint Committee on Cancer (AJCC) 8th edition TNM classification.[11]

Depth of invasion was measured from the basement membrane of the adjacent normal mucosa to the deepest point of tumour invasion as recommended by AJCC 8th edition.[11]

Worst pattern of invasion was assessed according to the criteria proposed by Brandwein-Gensler et al., and categorised into WPOI grades 1 to 5.[12]

Histopathological examination

Tissue specimens were fixed in 10% neutral buffered formalin, processed using an automated tissue processor (MYR STP-120 Electra, Spain), embedded in paraffin, sectioned at 3–4 µm thickness and stained with hematoxylin and eosin

(H&E). Histopathological examination was independently performed by two experienced pathologists.

Immunohistochemistry

Immunohistochemistry for CD44 was performed on representative formalin-fixed paraffin-embedded tissue sections using mouse monoclonal anti-CD44 antibody (Clone MRQ-13, ready-to-use). Three-micrometre-thick sections were mounted on poly-L-lysine-coated slides.

Following deparaffinization and rehydration, antigen retrieval was carried out using citrate buffer (pH 6.0) in an autoclave. Endogenous peroxidase activity was blocked, followed by incubation with the primary antibody. Immunostaining was performed using a streptavidin-biotin-peroxidase detection system according to the manufacturer's instructions. Diaminobenzidine (DAB) was used as chromogen and hematoxylin as counterstain. Reactive lymphocytes served as internal positive controls. [13]

Evaluation of CD44 immunoexpression

Membranous staining of tumour cells was considered positive for CD44 expression.

CD44 immunoexpression was evaluated separately in the central tumour region and at the peripheral invasive front, as described by Boxberg et al. [14] The central region was defined as the middle portion of tumour nests, whereas the peripheral region corresponded to the invasive margin of the tumour.

For each case, five representative high-power fields (×400) were selected and at least 100 tumour cells were evaluated.[15]

Quantification score

The percentage of positively stained tumour cells was categorised as follows: [6]

- Score 1: <25% positive cells
- Score 2: 25–75% positive cells
- Score 3: >75% positive cells

Intensity score

Staining intensity was graded semi-quantitatively as:

- Mild (+)
- Moderate (++)
- Strong (+++)

Overall CD44 expression

Overall CD44 expression was determined after evaluation of the entire tumour section, taking into consideration the staining patterns observed in both the tumour centre and invasive front in the hotspot area.

All slides were independently evaluated by two pathologists blinded to clinicopathological data. Cases with discordant interpretations were reviewed jointly to achieve consensus.

Statistical analysis

Data were analysed using IBM SPSS Statistics version 27.0 (IBM Corp., Armonk, NY, USA). Continuous variables were expressed as mean ± standard deviation, while categorical variables were presented as frequencies and percentages. Associations between variables were analysed using the Chi-square test or Fisher's exact test, as appropriate. A p-value <0.05 was considered statistically significant.

Ethics Committee Approval:

The study protocol was approved by the **Institutional Ethics Committee, Dr. D. Y. Patil Medical College, Hospital and Research Centre, Pune, Maharashtra, India** (Research Protocol No. **IESC/FP/36/2026**). The study was conducted in accordance with the ethical principles of the Declaration of Helsinki.

3. Results

Clinicopathological characteristics

A total of 100 patients with histopathologically confirmed OSCC were included in the study. The mean age of the patients was 54.3 ± 12.8 years. The highest number of patients belonged to the 51–60 years age group (36%).

With regard to habit history, tobacco chewing was the most common habit, reported by 50% of the patients, followed by the combined habit of smoking and tobacco chewing (38%). Smoking alone was reported by 12% of the patients.

The gingivobuccal sulcus was the most frequently affected site (30%), followed by the tongue (25%), buccal mucosa (22%), retromolar trigone (18%), and angle of the mandible (5%).

Most tumours measured 2–4 cm in greatest dimension (52%), while 26% measured more than 4 cm and 22% measured less than 2 cm.

Regional lymph node metastasis was present in 40% of the cases, whereas 60% showed no lymph node involvement. Perineural invasion was identified in 4% of cases, while 96% showed no evidence of perineural invasion.

Histopathologically, moderately differentiated squamous cell carcinoma (MDSCC) was the most common subtype, accounting for 46% of cases, followed by well-differentiated squamous cell carcinoma (WDSCC) (34%) and poorly differentiated squamous cell carcinoma (PDSCC) (20%).

Histopathology and CD44 immunoexpression of WDSCC and MDSCC are shown in Figure 1A–D. The association between overall CD44 immunoexpression and clinicopathological parameters is summarized in Table 1.

Table 1. Association of overall CD44 expression with clinicopathological parameters in OSCC (n = 100)

Parameter	Category	CD44 <25%	CD44 25–75%	CD44 >75%	χ^2 (df)	p-value
Histological grade	WDSCC	0	20	14	13.93 (2)	≈0.001
	MDSCC	0	26	20		
	PDSCC	0	20	0		
Pathological tumour stage (pT)	T1	0	4	8	18.11 (2)	<0.001
	T2	0	12	16		
	T3	0	24	8		
	T4	0	24	4		
Regional lymph node stage (pN)	pNX	0	4	0	8.62 (6)	0.196
	pN0	0	32	16		
	pN1	0	16	4		
	pN2	0	4	0		
	pN2b	0	0	8		
	pN2c	0	8	0		
	pN3b	0	4	4		
Worst Pattern of Invasion (WPOI)	WPOI 1	0	0	0	14.64 (3)	≈0.006
	WPOI 2	0	10	0		
	WPOI 3	0	20	10		
	WPOI 4	0	16	20		
	WPOI 5	0	20	4		

Table note: Values are numbers of cases. The <25% CD44 expression category contained zero cases in all reported groups. WDSCC, well-differentiated squamous cell carcinoma; MDSCC, moderately differentiated squamous cell carcinoma; PDSCC, poorly differentiated squamous cell carcinoma; WPOI, worst pattern of invasion.

Overall CD44 expression demonstrated statistically significant associations with histological grade ($\chi^2 = 13.93$, $p = 0.001$), pathological tumour stage ($\chi^2 = 17.74$, $p < 0.001$), and worst pattern of invasion ($\chi^2 = 14.64$, $p = 0.006$). The proportion of CD44 expression was increased in all poorly differentiated carcinoma and with WPOI 4 lesions.

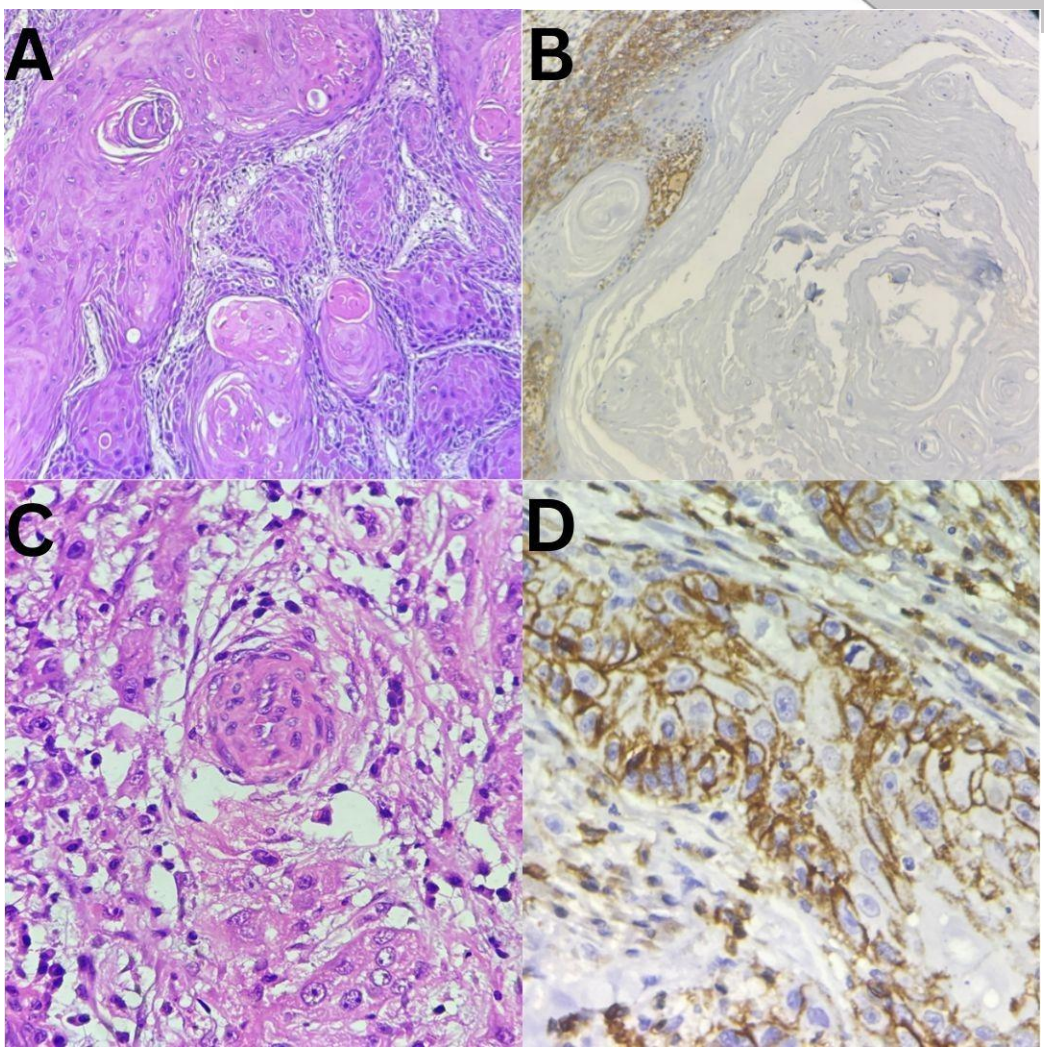

Figure 1. Histopathology and CD44 immunohistochemistry in OSCC. (A) Well-differentiated squamous cell carcinoma with keratin pearl formation and stromal invasion (H&E, ×100). (B) CD44 staining in well-differentiated squamous cell carcinoma, showing negative keratinised areas and moderate membranous staining of adjacent tumour cells (IHC, ×100). (C) Moderately differentiated squamous cell carcinoma showing nuclear pleomorphism and hyperchromasia (H&E, ×400). (D) Strong membranous CD44 staining at the tumour periphery (IHC, ×400).

Peripheral CD44 immuno expression

Peripheral CD44 immunoexpression was assessed at the invasive front in all cases. Uniform strong membranous staining (>75% positive tumour cells with +++ intensity) was observed in all 100 cases, irrespective of clinicopathological characteristics. Owing to the absence of variability in peripheral CD44 expression, statistical comparison with clinicopathological parameters was not feasible. Due to the lack in variability, overall expression of CD44 was critically assessed in this study.

4. Discussion

OSCC remains a major global health burden, particularly in countries with a high prevalence of tobacco consumption. [1–3,16] Despite advances in diagnosis and treatment, predicting tumour behaviour using conventional clinicopathological parameters alone remains challenging. Cancer stem cell markers such as CD44 have therefore gained considerable attention because of their role in tumour initiation, invasion, progression, and therapeutic resistance. [4–7,17] The present study evaluated overall CD44 immunoexpression in relation to established clinicopathological prognostic factors in OSCC.

The clinicopathological profile of the present study was comparable with that reported in the literature. Most patients belonged to the fifth and sixth decades of life, tobacco chewing was the predominant habit, and the gingivobuccal sulcus was the most frequently affected site, reflecting the epidemiological pattern of OSCC in the Indian population. [1–3,16] Moderately differentiated squamous cell carcinoma constituted the largest histological subgroup, which is in agreement with previous reports. [5,6]

Overall CD44 expression differed by histological grade in this series, with high expression in well- and moderately differentiated carcinomas but not in poorly differentiated tumours. Hema et al. reported significantly higher CD44s immunoexpression in well-differentiated than in poorly differentiated OSCC, whereas Boxberg et al. linked invasive-margin CD44 overexpression to poor differentiation and tumour budding.[14,18] These apparently divergent findings underscore the importance of antibody specificity, tumour compartment and scoring method. The relevant published studies are compared with our observations in Table 2.

Table 2. Comparison of published CD44 studies with the present OSCC series

Study / reference	Published study: method and principal finding	Comparison with present study
Chakraborty et al. (2024) [6]	105 OSCC; tissue IHC; 87.5% showed CD44 expression. Higher expression occurred in advanced TNM stages and was associated with nodal metastasis ($p < 0.001$).	Stage-related findings broadly agree, but the reported nodal association contrasts with the present non-significant result.
Hema et al. (2014) [18]	30 OSCC; CD44s IHC. Expression was greatest in well-differentiated tumours and declined with poorer grade; nodal-status association was not significant.	Grade trend and lack of nodal association are directionally similar; the isoform and scoring method differ.
Boxberg et al. (2018) [14]	108 OSCC; compartment-based IHC. Overexpression occurred in 37% at tumour centre and 39% at invasive margin, with associations with budding/poor differentiation; survival analyses were reported.	Peripheral expression varied in their series, unlike the uniform strong invasive-front staining here; scoring and thresholds are not interchangeable.
Petrović et al. (2025) [5]	12 OSCC; flow cytometry of tumour-derived cell cultures. Median CD44 positivity was 96.4%; DOI-related correlations primarily concerned other markers/co-expression.	Shows widespread CD44 positivity by a different assay; does not validate tissue-IHC stage or WPOI associations.
Mirhashemi et al. (2023) [19]	Meta-analysis of 11 IHC studies (1,084 OSCC patients): high CD44 expression was associated with poorer overall and disease-free survival.	Provides outcome context, but the present cohort has no survival follow-up and cannot test prognostic validity.
Poothakulath Krishnan et al. (2023) [20]	Systematic review (nine eligible studies) of CD44/CD24 phenotypes; no consistent correlation of the assessed CD44/CD24 patterns with disease-free survival.	Highlights heterogeneity; combined-marker immunophenotypes are not directly comparable to CD44-only scoring.

IHC, immunohistochemistry; OSCC, oral squamous cell carcinoma; DOI, depth of invasion; WPOI, worst pattern of invasion. CD44 thresholds and assay platforms varied across studies; direct quantitative comparison is inappropriate.

In our cohort, overall CD44 categories also differed by pathological tumour category. Chakraborty et al. reported higher CD44 expression in advanced TNM stages, but their outcome was stage group rather than pathological T category alone.[6] The small flow-cytometry study by Petrović et al. documented widespread CD44 positivity without establishing comparable immunohistochemical pT associations.[5]

The distribution of overall CD44 expression also varied across worst-pattern-of-invasion (WPOI) categories. In the supplied case table, the >75% staining category was most frequent in WPOI 4, whereas fewer WPOI 5 cases had >75% staining. Thus, the pattern should not be described as a simple stepwise increase with WPOI severity. WPOI is an established adverse histopathological feature; its relationship to CD44 should be explored in larger, independently validated series.[8,9,12]

All 100 cases showed strong membranous CD44 staining at the invasive front, precluding correlation of peripheral staining intensity with clinicopathological variables. By comparison, Boxberg et al. reported invasive-margin CD44 overexpression in 39% of 108 OSCCs using their own assessment protocol.[14] The difference may reflect definitions, antibody/scoring methods, or case mix and should not be interpreted as independent evidence of invasion or survival benefit. A published retrospective study protocol by Tehzeeb et al. does not itself provide outcome evidence.[15]

Overall CD44 expression was not significantly associated with regional lymph node status in the present series (reported $p = 0.196$). This differs from the 105-case study by Chakraborty et al., which found a significant association with nodal metastasis. Conversely, Hema et al. did not identify a significant nodal-status association in their smaller series.[6,18] The systematic review by Chen et al. found no clear clinicopathological association specifically in oral-cancer subgroups, reinforcing heterogeneity across studies.[7]

The studies in Table 2 demonstrate substantial heterogeneity in staining compartments, assays, cut-offs and clinical endpoints. Meta-analysis of immunohistochemical OSCC studies has associated high CD44 expression with worse survival, but the present cross-sectional study cannot assess recurrence or survival and cannot validate an independent prognostic role.[19] A separate review of combined CD44/CD24 immunophenotypes did not find a consistent relationship with disease-free survival, further emphasising assay dependence.[20]

Limitations include the single-centre design, lack of survival follow-up, evaluation of only one immunomarker without CD44 variant isoform analysis, and non-standardised comparability with published scoring systems. The reported inferential statistics and subgroup totals have not yet been independently re-analysed against patient-level data; final conclusions require that verification. Future prospective studies should use predefined compartments and scoring thresholds, with follow-up and multivariable prognostic models.

A practical strength is that both tumour-centre/whole-section expression and the peripheral invasive front were evaluated in 100 surgically resected cases, alongside histological grade, pT, nodal status and WPOI. The uniform peripheral signal is an informative negative finding for the discriminatory value of that compartment under the scoring method used.

5. Conclusion

The present study demonstrated a significant association between *overall CD44 immunoexpression and key clinicopathological parameters, including histological grade, pathological tumour stage, and worst pattern of invasion,* indicating that CD44 expression reflects important biological events involved in tumour progression and local invasion in OSCC. The consistent strong expression of CD44 at the invasive front further supports its role in maintaining the invasive tumour phenotype and reinforces the concept of spatial heterogeneity within the tumour microenvironment. Although no significant association was observed with regional lymph node metastasis, the overall findings suggest that *CD44 has potential as an adjunctive biomarker for identifying biologically aggressive tumours when interpreted alongside established histopathological prognostic indicators.* Standardisation of immunohistochemical scoring methods and further multicentric prospective studies incorporating survival outcomes and CD44 isoform analysis are required before CD44 can be recommended for routine prognostic use in clinical practice.

Funding: The authors received no specific funding for this work.

Conflict of Interest: The authors declare no conflict of interest.

Data Availability Statement: The data supporting the findings of this study are available from the corresponding author upon reasonable request.

Acknowledgements

The authors sincerely acknowledge the Department of Pathology, Dr. D. Y. Patil Medical College, Hospital and Research Centre, Pune, Maharashtra, India, for providing the facilities and infrastructure required to conduct this study. The authors also thank all the patients who consented to participate in this research.

References

1. Bray F, Laversanne M, Sung H, Ferlay J, Siegel RL, Soerjomataram I, et al. Global cancer statistics 2022: GLOBOCAN estimates of incidence and mortality worldwide for 36 cancers in 185 countries. CA Cancer J Clin. 2024;74(3):229-263. doi:10.3322/caac.21834.
2. Tan Y, Wang Z, Xu M, Li B, Huang Z, Qin S, et al. Oral squamous cell carcinomas: state of the field and emerging directions. Int J Oral Sci. 2023;15(1):44. doi:10.1038/s41368-023-00249-w.
3. Gangane NM, Ghongade PV, Patil BU, Atram M. Oral cavity cancer incidence and survival trends: A population-based study. J Cancer Res Ther. 2024;20(5):1446-1452. doi:10.4103/jcrt.jcrt_2720_22.
4. Acharya SK, Shai S, Choon YF, Gunardi I, Hartanto FK, Kadir K, et al. Cancer stem cells in oral squamous cell carcinoma: a narrative review on experimental characteristics and methodological challenges. Biomedicines. 2024;12(9):2111. doi:10.3390/biomedicines12092111.
5. Petrović A, Mojsilović S, Bugarski D, Jauković A, Pokimica B, Ilić MP. Expression of putative cancer stem cell markers in oral squamous cell carcinoma: correlation with clinicopathological features. Int J Mol Sci. 2025;26(22):10939. doi:10.3390/ijms262210939.
6. Chakraborty S, Suresh TN, Azeem Mohiyuddin SM. Expression of stem cell biomarker CD44 in oral squamous cell carcinoma and its association with lymph node metastasis and TNM staging. J Cancer Res Ther. 2024;20(5):1430-1434. doi:10.4103/jcrt.jcrt_178_23.
7. Chen J, Zhou J, Lu J, Xiong H, Shi X, Gong L. Significance of CD44 expression in head and neck cancer: a systemic review and meta-analysis. BMC Cancer. 2014;14:15. doi:10.1186/1471-2407-14-15.
8. Mishra A, Das A, Dhal I, Shankar R, Bhavya BM, Singh N, et al. Worst pattern of invasion in oral squamous cell carcinoma is an independent prognostic factor. J Oral Biol Craniofac Res. 2022;12(6):771-776.
9. Binmadi NO, Mohamed YA. Impact of worst pattern of invasion on prognosis of oral squamous cell carcinoma: A systematic review and meta-analysis. J Int Med Res. 2023;51(10):3000605231206260. doi:10.1177/03000605231206260.
10. El-Naggar AK, Chan JKC, Grandis JR, Takata T, Slootweg PJ, editors. WHO Classification of Head and Neck Tumours. 4th ed. Lyon: IARC Press; 2017.
11. Amin MB, Edge SB, Greene FL, Byrd DR, Brookland RK, Washington MK, et al. AJCC Cancer Staging Manual. 8th ed. New York: Springer; 2017.
12. Brandwein-Gensler M, Teixeira MS, Lewis CM, Lee B, Rolnitzky L, Hille JJ, et al. Oral squamous cell carcinoma: histologic risk assessment, but not margin status, is strongly predictive of local disease-free and overall survival. Am J Surg Pathol. 2005;29(2):167-78.
13. Shi SR, Cote RJ, Taylor CR. Antigen retrieval immunohistochemistry: past, present and future. J Histochem Cytochem. 1997;45(3):327-43.
14. Boxberg M, Götz C, Haidari S, Dorfner C, Jesinghaus M, Drecoll E, et al. Immunohistochemical expression of CD44 in oral squamous cell carcinoma in relation to histomorphological parameters and clinicopathological factors. Histopathology. 2018;73(4):559-572. doi:10.1111/his.13496.
15. Tehzeeb H, Gawande M, Hande A, Patil S, Sonone A, Pakhale A. Protocol for evaluation and correlation of CD44 immunoexpression in tumor tissue and surgical margins of oral squamous cell carcinoma with three-year survival: a retrospective study [study protocol; peer review awaiting]. F1000Research. 2023;12:773. doi:10.12688/f1000research.134510.1.
16. Warnakulasuriya S. Global epidemiology of oral and oropharyngeal cancer. Oral Oncol. 2020;102:104551.
17. Prince ME, Sivanandan R, Kaczorowski A, Wolf GT, Kaplan MJ, Dalerba P, et al. Identification of a subpopulation of cells with cancer stem cell properties in head and neck squamous cell carcinoma. Proc Natl Acad Sci U S A. 2007;104(3):973-

978. doi:10.1073/pnas.0610117104.
18. Hema KN, Rao K, Devi HSU, Priya NS, Smitha T, Sheethal HS. Immunohistochemical study of CD44s expression in oral squamous cell carcinoma-its correlation with prognostic parameters. J Oral Maxillofac Pathol. 2014;18(2):162-168. doi:10.4103/0973-029X.140722.
19. Mirhashemi M, Sadeghi M, Ghazi N, Saghravanian N, Dehghani M, Aminian A. Prognostic value of CD44 expression in oral squamous cell carcinoma: a meta-analysis. Ann Diagn Pathol. 2023;67:152213. doi:10.1016/j.anndiagpath.2023.152213.
20. Poothakulath Krishnan R, Pandiar D, Ramani P, Ramalingam K, Jayaraman S. Utility of CD44/CD24 in the outcome and prognosis of oral squamous cell carcinoma: a systematic review. Cureus. 2023;15(8):e42899. doi:10.7759/cureus.42899.