Research Article

Radiomorphometric Analysis Of Incisive Canal Using Cone Beam Computed Tomography – A Cross-Sectional Study

Badari Ramakrishna Botu[1], Rahul Marshal Vaddeswarapu[2], Rajesh Nallakunta[3], Kosuri Venkata Lokesh[4], Sheik Samruth Unnisa[5], Sharon Koppala[6], Muskan Shaik[7]

[1st] Badari Ramakrishna Botu, Professor and Head of the department Department of Oral Medicine and Radiology Anil Neerukonda Institute of Dental Sciences Visakhapatnam, Andhra Pradesh, India EMAIL-badari.botu@gmail.com

[2]Rahul Marshal Vaddeswarapu, Professor Department of Oral Medicine and Radiology Anil Neerukonda Institute of Dental Sciences Visakhapatnam, Andhra Pradesh, India EMAIL vrmars002@gmail.com

[3]Rajesh Nallakunta, Professor Department of Oral Medicine and Radiology Anil Neerukonda Institute of Dental Sciences Visakhapatnam, Andhra Pradesh, India EMAIL-rajeshcap09@gmail.com

[4] Kosuri Venkata Lokesh, Associate Professor Department of Oral Medicine and Radiology Anil Neerukonda Institute of Dental Sciences Visakhapatnam, Andhra Pradesh, India EMAIL-lokesh.kosuri123@gmail.com

[5]Sheik Samruth Unnisa, Post Graduate Student Department of Oral Medicine and Radiology Anil Neerukonda Institute of Dental Sciences Visakhapatnam, Andhra Pradesh, India EMAIL-unnisasamruth@gmail.com

[6]Sharon Koppala, Post Graduate Student Department of Oral Medicine and Radiology Anil Neerukonda Institute of Dental Sciences Visakhapatnam, Andhra Pradesh, India EMAIL-drsharon12@gmail.com

[7] Muskan Shaik, Under Graduate Student Department of Oral Medicine and Radiology Anil Neerukonda Institute of Dental Sciences Visakhapatnam, Andhra Pradesh, India EMAIL-muskanshaik270902@gmail.com

Corresponding Author: Kosuri Venkata Lokesh *

EMAIL- lokesh.kosuri123@gmail.com

Abstract

Background: The incisive canal is an important anatomical structure located in the anterior maxilla, serving as a passage between the oral and nasal cavities. Assessment of its anatomical and morphological variations is essential for dental implant placement and surgical procedures. Aim: To evaluate the radiomorphometric characteristics of the incisive canal using cone beam computed tomography (CBCT) with respect to gender and dentition status. Materials and Methods: A cross-sectional study was conducted over two months in the Department of Oral Medicine and Radiology at a tertiary care teaching hospital in Visakhapatnam. A total of 50 CBCT scans of the maxilla, including 25 males and 25 females, were evaluated. The length, diameter, shape, and entrance of the incisive canal in relation to the alveolar ridge were assessed using axial, coronal, and sagittal sections. Statistical analysis was performed using an independent t-test, one-way ANOVA, and the chi-square test. Results: The mean length of the incisive canal was 12.14 mm in males and 10.25 mm in females, showing a statistically significant difference ($p = 0.009$). Canal length also showed a significant difference based on dentition status ($p = 0.03$). The mean canal diameter was 3.94 mm in males and 3.48 mm in females, with no statistically significant difference ($p = 0.281$). Cylindrical and funnel-shaped configurations were the most frequently observed. No significant association was found between canal shape and gender ($p = 0.736$). The distance between the incisive canal entrance and the alveolar ridge showed no statistically significant differences based on gender or dentition status. Conclusion: The incisive canal exhibits anatomical and morphometric variations, with significant differences in canal length according to gender and dentition status. Three-dimensional evaluation using CBCT is valuable for understanding these variations, improving surgical treatment planning, and minimizing the risk of neurovascular injury during procedures involving the anterior maxilla.

Keywords: Incisive canal; Cone beam computed tomography; Nasopalatine canal; Radiomorphometric analysis; Alveolar ridge; Anterior maxilla; Anatomical variations.

1. Introduction

The recuperation of the maxillary anterior part is a challenge in both surgical and prosthetic aspects. The major challenge in the anterior maxilla, is the location of the incisive canal.[1] The incisive canal is situated in the hard palate anteriorly and serves as a passage between the oral and nasal cavities. Vital structures such as nasopalatine nerve and vessels exists here. The incisive canal terminates at the incisive fossa in maxilla behind the central incisors, beneath the incisive papilla. Superiorly, it extends to the nasal cavity on each side of the nasal septum.[2]

Studies on the development of the incisive canal during intrauterine life, as well as the occasionally associated nasopalatine duct showed controversial results and because of its anatomical and morphological variations and its location, it is of utmost important to study and evaluate the three-dimensional anatomy of the incisive canal for proper diagnosis and treatment plan. [3]

Where in conventional imaging techniques such as lateral cephalograms, Intraoral periapical radiographs and OPG may

not provide us with the detailed information and a clear three-dimensional view of incisive canal in the anterior maxilla, Cone-beam computed tomography (CBCT) studies have improvised head and neck imaging and has helped in understanding the anatomical and morphological differences of the incisive canal. Studies of the incisive canal using CBCT have shown that many factors such as age, gender, tooth loss and trauma can affect the metrics of the canal. These factors have led to special considerations and novel surgical techniques in oral–maxillofacial surgery.[4]

Cone beam computed tomography (CBCT) studies have improved to understand the anatomical as well as morphological differences in three-dimensional aspect of the canal, in terms of position, length, diameter and shape. long term studies have shown that factors such as age, gender, tooth loss, and trauma are the affecting factors for its measurements.

2. Materials And Methods:

A cross-sectional study was conducted over a period of two months in the Department of Oral Medicine and Radiology of a tertiary care teaching hospital in Visakhapatnam, with a sample size of 50 patients. CBCT scans of the maxilla from both male and female patients above 18 years of age, who were dentate, partially edentulous, or completely edentulous, were evaluated after satisfying the inclusion and exclusion criteria. Scans showing deviation between the anterior nasal spine and the midline of the dentition, evident bone loss, lesions involving the periapical area of the maxillary central incisors, impacted anterior teeth, a history of surgery in the specific area, or cysts or tumors involving the nasopalatine canal or incisive canal were excluded.

The selected CBCT scans were examined in axial, coronal, and sagittal sections to assess and measure the length, diameter, and shape of the incisive canal, as well as the position of its entrance on the alveolar ridge.

The length of the canal was measured in the sagittal section, in millimeters, from the incisive foramen to the nasopalatine foramen. (fig:1)

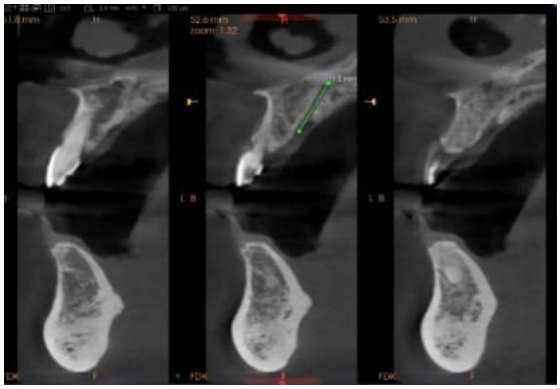

FIGURE 1: length of the canal

The shape of the canal was also evaluated in the sagittal section and classified as banana-shaped, funnel-shaped, cylindrical, or Y-shaped. (fig:2)

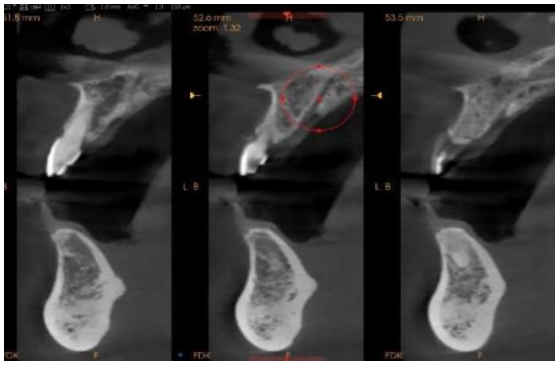

FIGURE 2: shape of the canal

The diameter of the canal was measured in the axial section along the mesiodistal direction. (fig:3)



FIGURE 3: Diameter of the canal

The entrance of the canal on the alveolar ridge was assessed in the sagittal section by measuring the distance from the incisive foramen to the alveolar ridge. (fig:4)

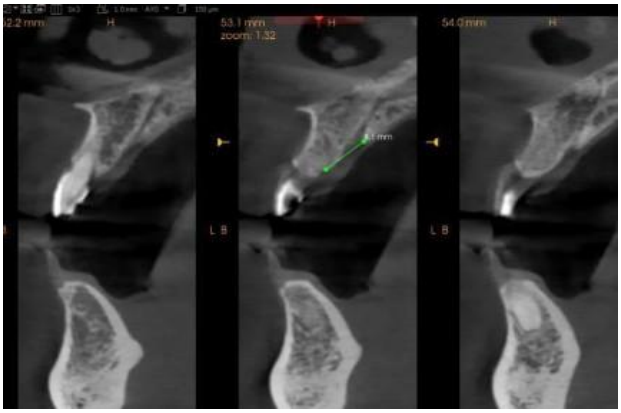

FIGURE 4: Entrance of the canal

3. Results:

A total of 50 CBCT scans of the maxilla, comprising 25 male and 25 female patients, were evaluated to assess the length, diameter, shape, and alveolar ridge entrance of the incisive canal.

	GENDER	MEAN	STD	T-VALUE	P-VALUE
AGE	MALES	36.24	18.65	0.104	0.918
	FEMALES	35.72	16.87		

The data were analysed using an independent t-test to compare the mean values of the parameters between genders, while one-way ANOVA was used to compare the mean values according to the type of dentition. Regarding the length of the incisive canal, the mean value was 12.14 mm in males and 10.25 mm in females, with a statistically significant difference between the genders ($p = 0.009$) [Table 2a]

	GENDER	MEAN	STD	T-VALUE	P-VALUE
LENGTH	MALES	12.14	2.72	2.74	0.009*
	FEMALES	10.25	2.07		

Table 2(a) Means of length of the incisive canal based on gender

Based on dentition, the mean canal length was 11.21 mm in dentate patients, 12.16 mm in partially edentulous patients, and 9.71 mm in completely edentulous patients, showing a statistically significant difference (p = 0.03) [Table 2b]

LENGHT	n	MEAN	STD	T-VALUE	P-VALUE
PARTIALLY EDENTULOU S	16	12.16	3.2	4.54	0.03*
EDENTULOU S	27	11.21	1.8		
DENTULOUS	7	9.71	1.24		

Table 2(b): Means of length of incisive canal based on dentition

The mean diameter of the incisive canal measured 3.94 mm in males and 3.48 mm in females, with no statistically significant difference (p = 0.281).[table3a] According to dentition, the mean diameter was 3.78 mm in dentate patients, 3.46 mm in partially edentulous patients, and 4.03 mm in completely edentulous patients; the difference was not statistically significant (p = 0.689). [table 3b].

	GENDER	**MEAN**	**STD**	**T-VALUE**	**P-VALUE**
DIAMETER	MALES	3.94	1.36	1.091	0.281
	FEMALES	3.48	1.60		

Table 3(a): Means of diameter of incisive canal based on gender

DIAMETER	n	MEAN	STD	T-VALUE	P-VALUE
PARTIALLY EDENTULOU S	16	3.468	1.39175	0.376	0.689
EDENTULOU S	27	3.785	1.54960		
DENTULOUS	7	4.033	1.65005		

Table 3(b): Means of diameter of incisive canal based on dentition

The shape of the incisive canal was evaluated in the sagittal section and classified into cylindrical, funnel, hourglass, Y-shaped, and banana-shaped types. The chi-square test showed no statistically significant association between canal shape and gender (p = 0.736).[table 4]

GENDER	CYLINDRICAL	FUNNEL	HOUR GLASS	Y-SHAPE	BANANA SHAPE
MALES	8 (16%)	8 (16%)	3 (6%)	4 (8%)	2 (4%)
FEMALES	7 (14%)	7 (14%)	2 (4%)	8 (16%)	1 (2%)
P-VALUE	0.736				

Table 4: Shape of the incisive canal

With regard to the distance between the incisive canal entrance and the alveolar ridge, the mean value was 7.84 mm in males and 7.49 mm in females, with no statistically significant gender difference (p = 0.533).[table 5a] Based on dentition, the mean distance was 7.89 mm in dentate patients, 7.23 mm in partially edentulous patients, and 7.93 mm in completely edentulous patients, with no statistically significant difference (p = 0.55).[table 5b]

LOCATION	GENDE R	MEA N	ST D	T-VALU E	P-VALU E
ENTRANCE OF CANAL TO THE ALVEOLAR RIDGE	MALES	7.84	1.8 5	0.6 28	0.5 33
ENTRANCE OF CANAL TO THE ALVEOLAR RIDGE	FEMALE S	7.49	2.1 4		

Table 5(a): Means of entrance of the incisive canal to the alveolar ridge based on gender

	N	MEAN	STD	F VALUE	P-VALUE
PARTAIALLY EDENTULOUS	16	7.2313	1.60030	0.606	0.55
DENTULOUS	27	7.8964	2.23234		
EDENTULOUS	7	7.9333	1.87688		

Table 5(b): Means of entrance of the incisive canal to the alveolar ridge based on dentition

4. Discussion

The incisive canal, also known as the nasopalatine canal, is a bony passage connecting the nasal and oral cavities through the anterior maxilla. It transmits important neurovascular structures, including the nasopalatine nerve and arterial branches that contribute to the blood supply of the anterior maxilla. The nasopalatine nerve provides sensory innervation to the mucosa of the hard palate and the gingiva surrounding the anterior teeth. In some cases, the nasopalatine duct may also be present as an additional structure within the canal.[1]

The anatomical location of the incisive canal is of particular clinical importance during surgical procedures and implant placement in the anterior maxilla. Injury to the nasopalatine nerve may result in hypoesthesia, paresthesia, or pain in the premaxillary region, while damage to the associated blood vessels may cause hemorrhage and subsequent compression of the nerve. Implant placement in the maxillary anterior region is challenging because of aesthetic and functional requirements and the close proximity of the incisive canal and foramen. Therefore, careful evaluation of the canal's morphology and dimensions is essential to minimize the risk of iatrogenic injury and other complications during dental procedures. males, while the Y-shaped configuration was more frequent in females. Hourglass and banana-shaped configurations were comparatively less common [2,3]

Tözüm et al. (2012) reported a mean incisive canal length of 10.86 ± 2.67 mm and observed shorter canals in patients with an edentulous anterior maxilla. Similarly, the present study showed a shorter mean canal length in completely edentulous patients (9.71 mm) compared with partially edentulous patients (12.16 mm).[5]

Khojastepour et al. (2017) reported that the width of the nasopalatine canal opening increased significantly with age, with the Y-shaped configuration being the most common.[6] Jayasinghe et al. (2020) reported a mean canal length of 12.142 mm and a mean diameter of 3.692 mm, with funnel shape being the most prevalent, followed by hourglass, banana, and cylindrical shapes. In comparison, the present study recorded mean canal lengths of 10.25 mm in females and 12.14 mm in males, with corresponding diameters of 3.48 mm and 3.94

mm. Cylindrical shape was the most prevalent, followed by funnel shape, while banana shape was the least common.[7] Kim et al. (2020) found that the anteroposterior diameter of the incisive foramen was greater than its mediolateral diameter and that canal dimensions were generally smaller in females. In the present study, the mediolateral diameter was 3.78 mm in dentate patients and 3.46 mm in partially edentulous patients.[8]

Gil-Marques et al. (2020) reported banana and funnel shapes as the most common configurations in dentate and edentulous patients, whereas cylindrical shape was predominant in the present study, followed by funnel shape. Their reported mean canal lengths were 10.9 ±

2.6 mm in dentate, 10.9 ± 3.5 mm in partially edentulous, and 10.9 ± 2.7 mm in completely edentulous patients, compared with 11.21 mm, 12.16 mm, and 9.71 mm, respectively, in the present study.[9] Al-Amery et al. (2015) highlighted variations in canal dimensions and morphology and reported that canal size was influenced by gender, although gender-related differences in incisive foramen dimensions remain inconclusive.[10] Similarly, Thakur et al. reported no significant association between gender and canal morphology.[12] Previous studies by Bornstein et al., and Mraiwa et al. reported mean canal lengths of 11.5 mm, 10.99 mm, and 8.1 mm, respectively. The influence of gender on canal length was significant in the present study, consistent with findings reported by Thakur et al. and Bornstein et al. Arnaut et al. (2021) reported a mean canal length exceeding 10 mm and an average incisive foramen diameter of 3.59 mm, while Mraiwa et al. reported a mean diameter of 4.6 mm. The incisive canal length in the present study ranged from 9 mm to 13 mm. [11]. [12], [13].

5. Conclusion

The incisive canal averages 10 mm in length and 6 mm in width, typically exhibiting a Y-shaped structure located about 2 cm from the nostrils. Its specific dimensions vary significantly based on a patient's age, gender, ethnicity, local trauma, or tooth loss. Evaluating this canal and the adjacent alveolar bone is highly critical to preventing neurovascular injury to the nasopalatine nerve and artery. Understanding these anatomical variations ensures proper implant osseointegration and successful nerve blocks during anterior tooth extractions. This structural knowledge is equally essential for planning other maxilla procedures, including guided bone regeneration, flap surgeries, and orthodontic treatments. Finally, because traditional two-dimensional radiographs lack precision, three-dimensional cone beam computed tomography (CBCT) serves as the definitive diagnostic tool for precise surgical planning.

References:

1. Ahmed STA, Da'er SAA, Homaid WAHA, AlShamahy HA, Mabkhout ANA, Khalid BSM, Al-Ankoshy AAM. Assessment the anatomical structure of canalis sinuous in the anterior maxilla to avoid surgical complications. Universal Journal of Pharmaceutical Research 2024; 9(4): 40-47
2. Lake S, Iwanaga J, Kikuta S, et al. The Incisive Canal: A Comprehensive Review. Cureus. 2018; 10 (7)
3. Kim YT, Lee JH, Jeong SN. Three-dimensional observations of the incisive foramen on cone-beam computed tomography image analysis. J Periodontal Implant Sci. 2020;50(1):48-55.
4. Alshomrani, F. Cone-Beam Computed Tomography (CBCT)-Based Diagnosis of Dental Bone Defects. Diagnostics. 2024; 14: 1404.
5. Margarita Bermúdez-Pérez1, Gloria Martínez- Sandoval1, María Gabriela Chapa-Arizpe1, Jesús Israel Rodríguez- Pulido1, Gustavo Israel Martínez-Gonzalez1. Evaluation of the incisive canal using cone beam computed tomography J. Inter.

Dent 2023 ;16(1):20-25
6. Khojastepour L, Haghnegahdar A, Keshtkar M. Morphology and dimensions of nasopalatine canal: a radiographic analysis using cone beam computed tomography. Journal of Dentistry. 2017 Dec;18(4):244.
7. Jayasinghe RM, Hettiarachchi PVKS, Fonseka MCN, Nanayakkara D, Jayasighe RD. Morphometric analysis of nasopalatine foramen in Sri Lankan population using CBCT. J Oral Biol Craniofac Res. 2020;10(2):238-240.
8. Kim YT, Lee JH, Jeong SN. Three-dimensional observations of the incisive foramen on cone-beam computed tomography image analysis. J Periodontal Implant Sci. 2020;50(1):48-55
9. Gil-Marques B, Sanchis-Gimeno JA, Brizuela-Velasco A, Perez-Bermejo M, Larrazábal-Morón C. Differences in the shape and direction-course of the nasopalatine canal among dentate, partially edentulous and completely edentulous subjects: B. Gil-Marques et al. Anatomical science international. 2020;95(1):76-84.
10. Al-Amery SM, Nambiar P, Jamaludin M, John J, Ngeow WC. Cone beam computed tomography assessment of the maxillary incisive canal and foramen: considerations of anatomical variations when placing immediate implants. PloS one. 2015 13;10(2):e0117251.
11. Thakur AR, Burde K, Guttal K, Naikmasur VG. Anatomy and morphology of the nasopalatine canal using cone-beam computed tomography. Imaging Sci Dent. 2013;43(4):273-281
12. Bornstein MM, Balsiger R, Sendi P, Von Arx T. Morphology of the nasopalatine canal and dental implant surgery: a radiographic analysis of 100 consecutive patients using limited cone-beam computed tomography. Clinical oral implants research. 2011;22(3):295-301.
13. Mraiwa N, Jacobs R, Van Cleynenbreugel J, Sanderink G, Schutyser F, Suetens P, van Steenberghe D, Quirynen M. The nasopalatine canal revisited using 2D and 3D CT imaging. Dentomaxillofacial Radiology. 2004 Nov 1;33(6):396-402.
14. Arnaut A, Milanovic P, Vasiljevic M, Jovicic N, Vojinovic R, Selakovic D, Rosic G. The shape of nasopalatine canal as a determining factor in therapeutic approach for orthodontic teeth movement: a CBCT study. Diagnostics. 2021; 11 (12): 2345 [Internet]. 2021