Research Article

Comparative Evaluation of 4% Ocimum sanctum Gel with and without 940 Nm Diode Laser as Adjuncts to Scaling and Root Planing in Periodontitis: A Randomized Controlled Clinical Trial

Dr. Soniya Lakshmi Jakka[1], Dr. Pallavi Samatha Yalamanchali[2], Dr. M.V. Ramojirao[3], Dr. Poojitha Mopidevi[4], Dr. Farhath Khatoon[5]

[1]Postgraduate, Department of Periodontics and Implantology, Drs. Sudha and Nageswara Rao Siddhartha Institute of Dental Sciences, Chinnaoutpalli, Gannavaram Mandal – 521286, Andhra Pradesh, India, soniyajakka429@gmail.com
[2]Professor, Department of Periodontics and Implantology, Drs. Sudha and Nageswara Rao Siddhartha Institute of Dental Sciences, Chinnaoutpalli, Gannavaram Mandal – 521286, Andhra Pradesh, India
[3]Professor and Head, Department of Periodontics and Implantology, Drs. Sudha and Nageswara Rao Siddhartha Institute of Dental Sciences, Chinnaoutpalli, Gannavaram Mandal – 521286, Andhra Pradesh, India
[4]Postgraduate, Department of Periodontics and Implantology, Drs. Sudha and Nageswara Rao Siddhartha Institute of Dental Sciences, Chinnaoutpalli, Gannavaram Mandal – 521286, Andhra Pradesh, India
[5]Postgraduate, Department of Periodontics and Implantology, Drs. Sudha and Nageswara Rao Siddhartha Institute of Dental Sciences, Chinnaoutpalli, Gannavaram Mandal – 521286, Andhra Pradesh, India

Abstract

Background: Scaling and root planing (SRP) often leaves residual pockets and inflammation. Ocimum sanctum (tulsi) has antimicrobial and anti-inflammatory properties, and diode lasers reduce pocket bacterial load and aid soft-tissue healing. Few trials have combined them. Aim: To compare SRP alone, SRP with 4% Ocimum sanctum gel, and SRP with 4% Ocimum sanctum gel plus 940 nm diode laser in chronic periodontitis. Methods: In this parallel-group randomized controlled trial, 30 systemically healthy adults aged 25–50 years with probing pocket depth (PPD) ≥5 mm were allocated to Group 1 (SRP), Group 2 (SRP + gel) or Group 3 (SRP + laser + gel), 10 per group. Plaque index (PI), gingival index (GI), modified sulcus bleeding index (mSBI), PPD and clinical attachment level (CAL) were recorded at baseline, day 21 and day 45, and analysed by repeated-measures and one-way ANOVA with post-hoc tests. Results: All parameters improved significantly within every group ($p \leq 0.001$). From baseline to day 45, Group 3 showed the largest reductions: PI 82.5%, GI 86.4%, mSBI 83.8% and PPD 2.81 mm (1.80 mm in Group 1; 1.81 mm in Group 2). At day 45, Group 3 had significantly lower GI, mSBI and PPD than both other groups. CAL gain was similar (2.30, 1.79 and 2.26 mm; between-group $p = 0.320$). Several baseline indices differed between groups. Conclusion: Adding 940 nm diode laser and 4% Ocimum sanctum gel to SRP produced greater short-term reductions in gingival inflammation, bleeding and pocket depth, without additional attachment gain. Larger trials with longer follow-up are needed.

Keywords: Ocimum sanctum; tulsi; diode laser; periodontitis; scaling and root planing; local drug delivery; randomized controlled trial

1. Introduction

Periodontitis is a chronic, multifactorial inflammatory disease of the tooth-supporting tissues. It starts with a dysbiotic subgingival biofilm and is sustained by the host's inflammatory response to it. Left untreated, it destroys the periodontal ligament and alveolar bone and ends in tooth loss.[1] Gram-negative anaerobes such as Porphyromonas gingivalis, Tannerella forsythia, Prevotella intermedia and Aggregatibacter actinomycetemcomitans dominate the subgingival flora of deep pockets. Their products drive the breakdown of collagen and bone through host-derived cytokines and enzymes.[1,2]

Mechanical debridement by scaling and root planing (SRP) remains the reference standard of non-surgical periodontal therapy. It disrupts the biofilm, removes calculus and leaves a clean, biocompatible root surface.[3] Its results are nonetheless uneven. Deep pockets, furcations and root concavities limit instrument access, and residual bacteria repopulate treated sites within weeks.[3] For this reason, chemical and physical adjuncts have been tested to improve what SRP alone achieves.

Local drug delivery (LDD) places an antimicrobial agent directly in the pocket. It reaches high concentrations at the site with little systemic exposure.[4] Goodson and colleagues first showed this principle in 1979 using tetracycline-filled fibres.[5] Tetracyclines, metronidazole, minocycline and chlorhexidine have since been used as local agents. These agents

act mainly against bacteria and have little antioxidant or host-modulating activity. They are also costly, are not always available, and carry a risk of resistance and local irritation.[4]

These drawbacks have renewed interest in plant-derived agents. Ocimum sanctum Linn. (tulsi, holy basil) of the family Lamiaceae is one of the most valued herbs in Ayurvedic medicine.[6] Its leaves contain eugenol, rosmarinic acid, apigenin, ursolic acid, luteolin and cirsilineol. These compounds have antimicrobial, anti-inflammatory, antioxidant and immunomodulatory effects.[6] In vitro, tulsi extract inhibits A. actinomycetemcomitans, P. gingivalis and P. intermedia, and at 5–10% concentration it approaches the activity of doxycycline.[7] A 2% tulsi gel reduced gingival inflammation and pocket depth in experimental periodontitis in rats without toxicity.[8]

Diode lasers (wavelength 805–980 nm) are widely used as an adjunct in non-surgical therapy. Their energy is absorbed by pigmented bacteria, haemoglobin and melanin. This lets them reduce the subgingival bacterial load, remove the inflamed pocket epithelium and help the soft tissue heal.[9,10] Clinical results, however, are inconsistent. A meta-analysis found no significant long-term benefit of adjunctive diode laser over SRP alone.[11] A recent split-mouth trial of a 980 nm laser likewise showed no added clinical or microbiological benefit.[12]

The effect of a diode laser depends on its wavelength and energy settings. Longer wavelengths in the diode range, such as 940 and 980 nm, are absorbed more by water than shorter ones such as 810 nm. This increases their effect on inflamed, oedematous soft tissue.[10] At higher power (1–2 W), the laser is used to remove the pocket epithelium and disinfect the pocket. At low power, it is used for photobiomodulation, which aims to speed healing and reduce inflammation without removing tissue.[10,12] Trials have used both approaches with SRP, and the two are often grouped together in reviews, which partly explains the mixed conclusions.

The two adjuncts act in different and possibly complementary ways. The laser disinfects the pocket and removes diseased epithelium at the time of treatment. The herbal gel can then supply antimicrobial and anti-inflammatory activity during healing. Herbal LDD and diode lasers have been compared as separate adjuncts,[13] but to our knowledge no trial has tested Ocimum sanctum gel together with a diode laser.

The aim of this trial was to evaluate 4% Ocimum sanctum gel as an adjunct to SRP and to compare it with the same gel combined with a 940 nm diode laser. The outcomes were plaque, gingival inflammation, bleeding, pocket depth and attachment level in patients with chronic periodontitis. The null hypothesis was that the three treatments would not differ in any clinical parameter at 45 days.

2. Materials And Methods

2.1 Study Design And Setting

This was a single-centre, three-arm, parallel-group randomized controlled clinical trial. It was conducted in the Department of Periodontics and Implantology, Drs. Sudha and Nageswara Rao Siddhartha Institute of Dental Sciences, Chinnaoutpalli, Gannavaram, Andhra Pradesh, India. The Institutional Ethics Committee approved the protocol. The study followed the Declaration of Helsinki (2013) and is reported according to the CONSORT 2010 statement. Every participant gave written informed consent in English or Telugu before enrolment.

2.2 Participants

Thirty patients with chronic periodontitis were recruited from the outpatient department. Inclusion criteria were: systemically healthy adults aged 25–50 years; at least one site with probing pocket depth (PPD) ≥5 mm and clinical attachment level (CAL) ≥5 mm; and a plaque index and gingival index score of ≥1. Exclusion criteria were: systemic antibiotic use within the previous 3 months; periodontal therapy within the previous 6 months; pregnancy or lactation; and any medical condition that could affect periodontal healing. Current smokers and users of any form of tobacco were also excluded. A detailed case history and a general medical examination were recorded on a structured proforma for each patient.

2.3 Sample Size, Randomization And Blinding

Assuming a 1.0 mm difference in PPD reduction (SD 0.7 mm), $\alpha = 0.05$ and 80% power, 8 patients per group were required; 10 per group were enrolled to allow for dropout. Patients were allocated 1:1:1 by a computer-generated

sequence, concealed in sealed opaque envelopes. The examiner and statistician were blinded to group allocation.
Group 1 (control): SRP alone
Group 2: SRP followed by subgingival 4% Ocimum sanctum gel
Group 3: SRP followed by 940 nm diode laser irradiation and subgingival 4% Ocimum sanctum gel

2.4 Preparation OF 4% Ocimum SANCTUM GEL

An accurately weighed quantity of carbomer (Acrypol 980) was dispersed in demineralised water and stirred slowly for 10–15 minutes until fully hydrated. Sodium benzoate and xylitol, dissolved in water, were added, and the dispersion was neutralised with sodium hydroxide solution. Carboxymethyl cellulose was dispersed in sorbitol solution and blended into the carbomer base with stirring. Tulasi leaf extract dissolved in the remaining water was then added with slow, constant stirring to a final concentration of 4% w/w. The composition and physical properties of the gel are given in Table 1.

Table 1. Composition and physical properties of the 4% Ocimum sanctum gel

Component or property	Function or value
Ocimum sanctum (tulasi) leaf extract, 4%	Active agent
Carbomer (Acrypol 980)	Gelling agent
Carboxymethyl cellulose	Viscosity modifier, mucoadhesive
Sorbitol solution	Humectant, vehicle
Xylitol	Sweetener, anticariogenic
Sodium benzoate	Preservative
Sodium hydroxide	Neutraliser
Demineralised water	Vehicle (to 100%)
Appearance	Brown, translucent gel
pH	6.5–7.5
Viscosity (Brookfield, 20 rpm)	45,000–50,000 cP

2.5 Clinical Procedures

Alginate impressions were made, and a customised acrylic stent was fabricated for each patient to standardise the position and angulation of the probe. Baseline parameters were then recorded. All patients received oral hygiene instruction and full-mouth SRP with ultrasonic scalers, followed by root planing with Gracey curettes, in a single session.

In Group 1, the selected sites received SRP alone. In Group 2, the site was isolated with cotton rolls and dried with an air syringe. The 4% Ocimum sanctum gel was then delivered into the pocket with a disposable syringe fitted with a 90°-bent blunt needle until the pocket was filled, and a periodontal dressing (Coe-Pak) was placed. In Group 3, the pocket was first irradiated with a 940 nm diode laser (Epic X, BIOLASE Inc., Irvine, CA, USA) at 2 W in continuous-wave mode. A 400 µm fibre tip was used in non-contact mode for 10 s per site. The gel and Coe-Pak were then placed as in Group 2. The patient, operator and assistant wore wavelength-specific protective eyewear during irradiation. Post-operative instructions were given to all patients, who were asked to avoid brushing or chewing on the treated area for 24 hours and to maintain oral hygiene elsewhere.

2.6 Outcome Measures

All parameters were recorded by a single calibrated examiner at baseline, day 21 and day 45 using a William's graduated periodontal probe with the acrylic stent. The 21-day interval was chosen because connective-tissue healing after non-surgical therapy is expected to be largely complete by then. The 45-day interval allowed early maturation of that healing to be assessed.

- **Plaque Index (PI)** of Silness and Löe,[14] scored 0–3 at four surfaces per tooth after a disclosing agent was applied.
- **Gingival Index (GI)** of Löe and Silness,[15] scored 0–3 at four gingival units per tooth.
- **Modified Sulcus Bleeding Index (mSBI)** of Mombelli et al.,[16] scored 0–3 after gentle probing along the gingival margin.
- **Probing Pocket Depth (PPD)**: distance from the gingival margin to the base of the pocket, in mm.

- **Clinical Attachment Level (CAL):** distance from the cemento-enamel junction to the base of the pocket, in mm.

PPD and CAL were measured to the nearest millimetre at six sites per tooth (mesiobuccal, mid-buccal, distobuccal, mesiolingual, mid-lingual and distolingual). For each patient, the values of all selected sites with PPD ≥5 mm were averaged, so the patient was the unit of analysis. The primary outcome was the change in PPD from baseline to day 45. Clinical photographs were taken before, during and after treatment.

Before the study, the examiner was calibrated by duplicate measurements of PPD and CAL, 24 hours apart, on five patients not enrolled in the trial; calibration was accepted when at least 90% of paired measurements agreed within ±1 mm. The same probe and stent were used at every visit. Index scores were interpreted using the original authors' categories. For PI: 0 indicates excellent oral hygiene, 0.1–0.9 good, 1.0–1.9 fair and 2.0–3.0 poor. For GI: 0.1–1.0 indicates mild, 1.1–2.0 moderate and 2.1–3.0 severe gingival inflammation.

2.7 Statistical Analysis

Data were analysed with SPSS version 23.0 (IBM Corp., Armonk, NY, USA). Results are expressed as mean ± standard deviation (SD). Changes within each group over the three time points were tested by repeated-measures ANOVA, followed by Bonferroni-adjusted pairwise comparisons. Groups were compared at each time point by one-way ANOVA with Bonferroni post-hoc tests. Because several baseline values differed between groups, the absolute and percentage change from baseline to day 45 was also calculated for each group. A two-sided $p < 0.05$ was considered significant.

3. Results

All 30 randomized patients received the allocated treatment and completed the 21-day and 45-day follow-up. No patient was lost and no adverse event was recorded.

3.1 Baseline Comparability

The groups were not balanced at baseline for four of the five parameters (Table 2, Table 3). Group 1 had lower PI (1.72 vs 2.33 and 2.40; $p < 0.001$) and GI (1.76 vs 2.15 and 2.35; $p < 0.001$) than Groups 2 and 3. It had higher mSBI (2.89 vs 2.25 and 2.35; $p < 0.001$) and deeper pockets than Group 2 (6.00 vs 5.29 mm; $p = 0.014$). Baseline CAL did not differ significantly between groups ($p = 0.058$).

3.2 Plaque, Gingival And Bleeding Indices

PI, GI and mSBI fell significantly from baseline to day 21 and again to day 45 in all three groups (all $p < 0.001$; Table 2, Figure 1). At day 45, Group 3 had the lowest GI (0.32 ± 0.10) and mSBI (0.38 ± 0.09). Its GI was significantly lower than in Group 1 ($p < 0.001$) and Group 2 ($p = 0.005$), and its mSBI was lower than in both ($p < 0.001$; Table 4). Group 2 had lower mSBI than Group 1 at both follow-ups ($p < 0.001$), but its GI did not differ from Group 1 at either visit. Day-45 PI was similar in Groups 1 and 3 (0.47 vs 0.42; $p = 1.000$) and higher in Group 2 (0.76; $p = 0.019$ and $p = 0.005$).

Table 2. Plaque, gingival and bleeding indices at baseline, day 21 and day 45 (mean ± SD, n = 10 per group)

Parameter	Group	Baseline	Day 21	Day 45	Intra-group F	Intra-group p
PI	1: SRP	1.72 ± 0.34	1.05 ± 0.30	0.47 ± 0.32	63.78	<0.001
PI	2: SRP + gel	2.33 ± 0.19	1.47 ± 0.15	0.76 ± 0.11	2167.36	<0.001
PI	3: SRP + laser + gel	2.40 ± 0.23	1.18 ± 0.19	0.42 ± 0.16	588.18	<0.001
PI	Inter-group F (p)	20.69 (<0.001)	9.17 (0.001)	7.06 (0.003)		
GI	1: SRP	1.76 ± 0.12	1.20 ± 0.31	0.78 ± 0.36	46.20	<0.001
GI	2: SRP + gel	2.15 ± 0.19	1.37 ± 0.15	0.68 ± 0.13	2755.53	<0.001
GI	3: SRP + laser + gel	2.35 ± 0.17	1.11 ± 0.15	0.32 ± 0.10	4959.95	<0.001
GI	Inter-group F (p)	33.26 (<0.001)	3.67 (0.039)	11.21 (<0.001)		
mSBI	1: SRP	2.89 ± 0.19	2.04 ± 0.21	1.38 ± 0.31	227.86	<0.001
mSBI	2: SRP + gel	2.25 ± 0.16	1.50 ± 0.12	0.92 ± 0.10	2928.07	<0.001
mSBI	3: SRP + laser + gel	2.35 ± 0.16	1.15 ± 0.13	0.38 ± 0.09	5218.06	<0.001
mSBI	Inter-group F (p)	42.17 (<0.001)	78.78 (<0.001)	64.55 (<0.001)		

Intra-group: repeated-measures ANOVA. Inter-group: one-way ANOVA. PI, plaque index; GI, gingival index; mSBI, modified sulcus bleeding index; SRP, scaling and root planing.

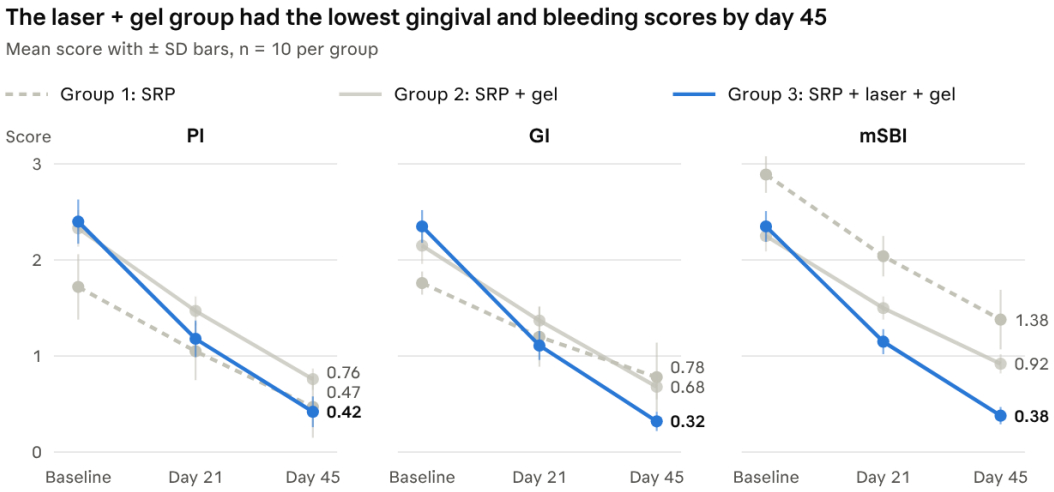

Figure 1. Plaque index (PI), gingival index (GI) and modified sulcus bleeding index (mSBI) at baseline, day 21 and day 45.

3.3 Probing Pocket Depth And Clinical Attachment Level

PPD decreased significantly in every group (Group 1, $p = 0.001$; Groups 2 and 3, $p < 0.001$; Table 3, Figure 2). Pocket reduction in Group 3 (2.81 mm) was about 1 mm greater than in Group 1 (1.80 mm) or Group 2 (1.81 mm). Group 3 reached a mean day-45 PPD of 2.87 ± 0.13 mm, significantly shallower than Group 1 (4.20 mm; $p < 0.001$) and Group 2 (3.48 mm; $p = 0.036$). At day 21, Group 3 already differed from Group 1 ($p < 0.001$) but not yet from Group 2 ($p = 0.176$). CAL improved significantly within all groups ($p < 0.001$), but the groups did not differ at day 21 ($p = 0.146$) or day 45 ($p = 0.320$). Mean attachment gain at day 45 was 2.30 mm in Group 1, 1.79 mm in Group 2 and 2.26 mm in Group 3.

In every group, most of the PPD reduction occurred in the first 21 days. Between day 21 and day 45, PPD fell by a further 0.80 mm in Group 1, 0.81 mm in Group 2 and 0.95 mm in Group 3. CAL, by contrast, improved more in the second interval in Groups 1 and 2, and about equally in both intervals in Group 3. Group 3 had the smallest standard deviations for PPD and CAL at day 45 (0.13 and 0.18 mm), indicating a more uniform response among its patients than in Group 1 (0.79 and 0.88 mm).

Table 3. Probing pocket depth and clinical attachment level at baseline, day 21 and day 45 (mm, mean ± SD, n = 10 per group)

Parameter	Group	Baseline	Day 21	Day 45	Intra-group F	Intra-group p
PPD	1: SRP	6.00 ± 0.67	5.00 ± 0.82	4.20 ± 0.79	22.88	0.001
PPD	2: SRP + gel	5.29 ± 0.28	4.29 ± 0.38	3.48 ± 0.36	140.56	<0.001
PPD	3: SRP + laser + gel	5.68 ± 0.52	3.82 ± 0.20	2.87 ± 0.13	197.08	<0.001
PPD	Inter-group F (p)	4.75 (0.017)	12.46 (<0.001)	17.35 (<0.001)		
CAL	1: SRP	6.40 ± 0.84	5.40 ± 0.97	4.10 ± 0.88	50.58	<0.001
CAL	2: SRP + gel	5.78 ± 0.32	5.17 ± 0.36	3.99 ± 0.41	82.60	<0.001
CAL	3: SRP + laser + gel	5.98 ± 0.36	4.83 ± 0.36	3.72 ± 0.18	375.19	<0.001
CAL	Inter-group F (p)	3.18 (0.058)	2.07 (0.146)	1.19 (0.320)		

Mean difference = first group minus second group. Bonferroni post-hoc test after one-way ANOVA. CAL is not shown because the overall ANOVA was not significant at either follow-up.

Table 4. Pairwise inter-group comparisons at day 21 and day 45: mean difference (p)

Parameter	Day	Group 1 vs 2	Group 1 vs 3	Group 2 vs 3
PI	21	−0.42 (0.001)	−0.13 (0.635)	0.29 (0.022)
PI	45	−0.29 (0.019)	0.05 (1.000)	0.34 (0.005)
GI	21	−0.17 (0.282)	0.09 (1.000)	0.26 (0.038)
GI	45	0.10 (0.963)	0.46 (<0.001)	0.36 (0.005)
mSBI	21	0.54 (<0.001)	0.89 (<0.001)	0.35 (<0.001)
mSBI	45	0.46 (<0.001)	1.00 (<0.001)	0.54 (<0.001)
PPD (mm)	21	0.71 (0.018)	1.18 (<0.001)	0.47 (0.176)
PPD (mm)	45	0.72 (0.011)	1.33 (<0.001)	0.61 (0.036)

Mean difference = first group minus second group. Bonferroni post-hoc test after one-way ANOVA. CAL is not shown because the overall ANOVA was not significant at either follow-up.

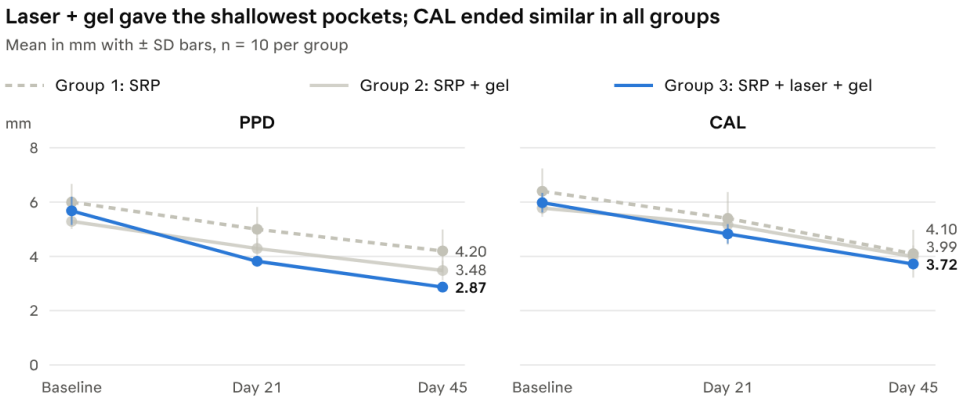

Figure 2. Probing pocket depth (PPD) and clinical attachment level (CAL) at baseline, day 21 and day 45.

3.4 Change From Baseline

Because baseline values differed, the change from baseline gives a fairer picture of treatment effect than the day-45 values alone (Figure 3). Group 3 showed the largest percentage improvement in every parameter, with clear margins for GI, mSBI and PPD. For CAL the margin was small: percentage gain ranged from 31% to 38% across groups, and Group 1 had the largest absolute gain (2.30 mm). Group 2 showed greater reductions than Group 1 in GI and mSBI, but its PPD reduction was about the same as Group 1 and its PI reduction was smaller.

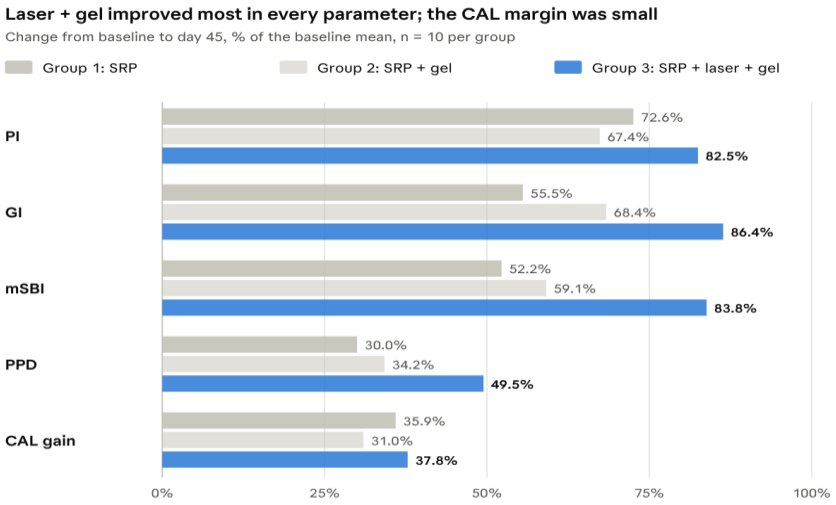

Figure 3. Percentage change from baseline to day 45 by group. For CAL, the bar shows attachment gain.

3.5 Clinical Illustration

Figure 4 shows the treatment sequence and follow-up at a representative Group 3 site. Probing was repeated with the same probe and acrylic stent at each visit, so that measurements were taken at the same position and angulation.

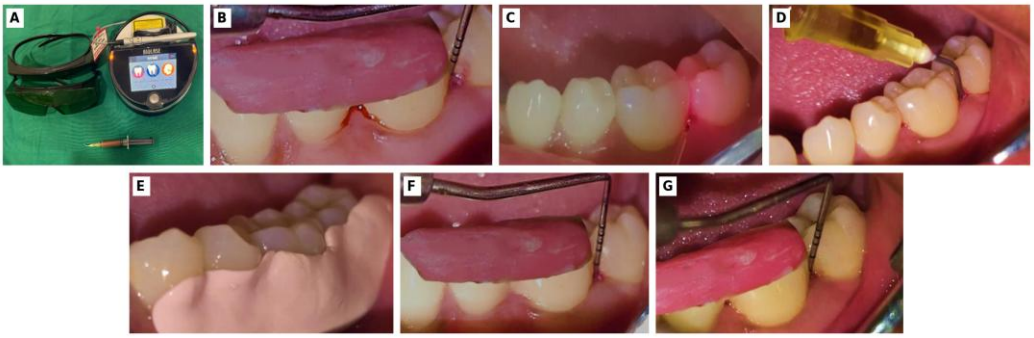

Figure 4. Clinical procedure and follow-up at a representative Group 3 site (SRP + 940 nm diode laser + 4% Ocimum sanctum gel). (A) 940 nm diode laser unit with protective eyewear and the 4% Ocimum sanctum gel in a disposable syringe. (B) Probing pocket depth and CAL recorded with a William's probe against the customised acrylic stent at baseline. (C) Intrapocket diode laser irradiation in non-contact mode after SRP. (D) Subgingival delivery of the gel with a bent blunt-tip syringe. (E) Periodontal dressing (Coe-Pak) in place. (F) Probing at day 21. (G) Probing at day 45.

4. Discussion

In this trial, all three treatments improved every clinical parameter over 45 days. Adding a 940 nm diode laser and 4% Ocimum sanctum gel to SRP gave the largest reductions in gingival inflammation, sulcular bleeding and pocket depth. PPD fell by 2.81 mm with the combination, against about 1.8 mm with SRP alone or SRP with gel. Clinical attachment gain, however, was no greater with either adjunct. The null hypothesis is therefore rejected for GI, mSBI and PPD, but not for CAL.

4.1 Ocimum Sanctum Gel As An Adjunct

The benefit of the gel used alone with SRP was modest and confined to soft-tissue inflammation. Compared with SRP alone, Group 2 showed a larger relative fall in GI (68% vs 56%) and mSBI (59% vs 52%) and lower bleeding scores at both follow-ups. Its PPD reduction, however, was the same as in Group 1 (1.81 vs 1.80 mm), and its attachment gain was smaller. These results fit the known pharmacology of tulsi. Eugenol, its main constituent, inhibits cyclo-oxygenase and lipoxygenase. Rosmarinic acid, ursolic acid and the flavonoids scavenge free radicals and modulate cytokine release.[6] Such actions would be expected to reduce gingival inflammation and bleeding more readily than they change pocket depth, which depends mainly on mechanical debridement and connective-tissue repair.

Thomas et al. used the same 4% concentration and the same 45-day interval in 60 patients. They found that adding the gel to SRP gave greater reductions in PI and PPD than SRP alone.[17] In our trial, the gel did not add pocket reduction, but our groups were small and Group 1 started with deeper pockets, which leaves more room for reduction. Deepika and Ramamurthy found a 2% tulsi gel as effective as tetracycline fibres for PPD and CAL over 8 months.[18] Rahalkar et al. and Agrawal et al. compared tulsi with curcumin as local agents. Both found significant clinical improvement and a fall in BAPNA activity, a marker of trypsin-like enzymes of red-complex bacteria.[19,20] Tulsi mouthwash has also matched chlorhexidine for plaque and gingival scores,[21,22] and tulsi extract inhibits periodontal pathogens in vitro.[7]

PI behaved differently from the other indices. Group 2 had the highest day-45 plaque score, and Groups 1 and 3 did not differ. Plaque control at 45 days depends mainly on the patient's home care, which was not standardised beyond oral hygiene instruction. A locally placed gel acts within the pocket and would not be expected to affect supragingival plaque on the whole dentition. The PI findings should therefore not be read as an effect, or lack of effect, of either adjunct.

Retention of the gel is a practical concern. Gingival crevicular fluid is replaced many times an hour, so a simple gel can

be washed out of the pocket quickly. The carbomer–carboxymethyl cellulose base used here has a viscosity of 45,000–50,000 cP and some mucoadhesion, and the Coe-Pak dressing helped to hold it in place. The concentration of active extract remaining in the pocket over time was not measured. A slow-release vehicle may give the extract more time to act.

The concentration of the extract may also have limited the gel's effect on pocket depth. In vitro, tulsi extract inhibited A. actinomycetemcomitans, P. gingivalis and P. intermedia most strongly at 5–10%, where its activity approached that of doxycycline.[7] The 4% gel used here sits below that range, and the concentration that reaches the base of a 5–6 mm pocket after dilution by crevicular fluid is lower still. Clinical trials have used concentrations from 2% to 10% with broadly positive results,[17–20] but no trial has compared concentrations directly. A dose-ranging study would show whether a higher concentration adds pocket reduction without irritating the tissues.

4.2 Diode Laser As An Adjunct

The laser group, which also received gel, achieved roughly 1 mm more pocket reduction and far lower bleeding scores than either other group. Diode lasers act in two ways relevant to these outcomes. The 805–980 nm energy is absorbed by pigmented anaerobes and haemoglobin, so it kills bacteria in the pocket wall and soft tissue that instruments do not reach.[9] It also removes the ulcerated sulcular epithelium and granulation tissue, coagulates small vessels and stimulates fibroblast activity, which favours early soft-tissue healing.[10] Moritz et al. showed that diode-laser irradiation eliminated more bacteria from pockets than scaling alone and improved bleeding on probing.[9] Removal of inflamed tissue and shrinkage of the pocket wall can explain the fast fall in PPD and mSBI seen in Group 3 by day 21.

The clinical literature on adjunctive diode lasers is divided. Dukic et al. found that repeated 980 nm irradiation after SRP reduced pocket depth more than SRP alone.[23] Nammour et al. reported greater PPD reduction and more pockets closing to ≤3 mm over 12 months with a 980 nm laser.[24] Matarese et al. found greater PPD and CAL improvement and short-term falls in orange-complex bacteria and IL-1β in aggressive periodontitis.[25] Kadhim Salman and Al-Ameri reported greater reductions in PPD and bleeding with a dual-wavelength laser.[26] Anwar et al. found intra-pocket diode laser as effective as systemic antibiotics in grade C periodontitis.[27]

Other trials found no added benefit. Caruso et al. reported no significant clinical or microbiological difference with a 980 nm laser,[28] and Sayar et al. found that a 940 nm laser lowered crevicular MMP-13 without improving clinical outcomes.[29] Dervisbegovic et al. likewise found no benefit with low-level 980 nm irradiation,[12] and the meta-analysis by Sgolastra et al. found no significant long-term advantage over SRP.[11] Differences in wavelength, power, pulse mode, exposure time and number of applications may explain much of this variation. Our protocol used 2 W for 10 s in non-contact mode in a single session, so these results apply to that protocol only.

Safety is relevant at the power used here. In contact mode, high-power diode lasers can raise root-surface temperature and char cementum, and they can damage the pulp or bone if exposure is prolonged.[10] These risks were limited here by the non-contact mode, a 10-second exposure per site and irradiation directed at the soft-tissue wall rather than the root. No thermal injury, unusual post-operative pain or adverse reaction to the gel was observed. Tulsi extract has a long record of oral use, and topical tulsi products have been used in trials without notable adverse effects.[6,21]

4.3 The Combined Adjunct And Attachment Level

The combination produced greater PPD reduction without greater CAL gain. This pattern indicates that part of the extra pocket reduction came from a more apical gingival margin rather than new attachment. Laser removal of inflamed epithelium and the resolution of oedema both shrink the pocket wall, which reduces PPD more than CAL. Recession was not recorded separately in this trial, so this explanation could not be confirmed.

Two further points apply to the CAL result. First, Group 1 showed a CAL gain (2.30 mm) larger than its PPD reduction (1.80 mm). This implies a coronal shift of the gingival margin, which is unusual after SRP. With measurements rounded to the nearest millimetre and 10 patients per group, such differences are within the range of measurement error. Second, true attachment gain is limited at 45 days. Long junctional epithelium forms early, but connective-tissue maturation and any bone fill continue for months. A longer follow-up would be needed to show whether the adjuncts change attachment.

The design cannot separate the effects of the laser and the gel. Group 3 received both, and there was no laser-only arm. The difference between Groups 2 and 3 estimates the effect of adding the laser to gel-supplemented SRP. It cannot show whether the laser alone would have done as well, or whether the two act together. A factorial design with SRP + laser alone would answer this question. Ganvir et al. compared a neem chip and a soft-tissue diode laser as separate adjuncts and found both better than SRP, with the herbal agent slightly ahead.[13]

The two adjuncts could act together in at least three ways, though none was tested here. First, the laser removes the inflamed epithelial lining, which may let the gel reach the underlying connective tissue more easily. Second, the gel's anti-inflammatory and antioxidant activity may limit the thermal and oxidative stress produced by irradiation. Third, the laser disinfects the pocket at the time of treatment, and the gel may slow bacterial recolonisation in the days that follow, when residual bacteria would otherwise repopulate the site.[3,9] Testing these ideas would need microbiological sampling and crevicular biomarkers at several early time points.

4.4 Time Course Of Healing

The pattern of change between visits gives further information. Bleeding scores separated early: by day 21, all three pairwise differences in mSBI were already significant. Pocket depth followed more slowly. Group 3 differed from Group 1 at day 21, but the difference between Groups 2 and 3 became significant only at day 45. This sequence fits the expected course of healing. Bleeding reflects the state of the pocket epithelium and the vessels beneath it, which respond within days to disinfection and de-epithelialisation. Pocket depth depends on resolution of oedema, connective-tissue maturation and formation of a long junctional epithelium, which take several weeks. The continued improvement between day 21 and day 45 in all groups suggests that healing was still under way at the last visit, and that the differences between groups may change with longer follow-up.

4.5 Baseline Imbalance

The groups differed at baseline in PI, GI, mSBI and PPD despite randomization, which is not unusual with only 10 patients per arm. These differences affect how the follow-up values can be read. Group 1 started with the highest bleeding scores and deepest pockets but the lowest PI and GI. Groups 2 and 3 started with more gingival inflammation, so they had more scope for reduction in GI. Day-45 comparisons between groups therefore partly reflect where each group began. We have reported change from baseline to reduce this bias. An analysis of covariance using baseline values as covariates would be the preferred method in a larger trial. Regression to the mean may also have inflated the reductions in the groups with the highest baseline scores.

4.6 Clinical Relevance

An extra 1 mm of pocket reduction is clinically meaningful at sites that start at 5–6 mm, because it can convert a site needing further treatment into one that can be maintained. The 940 nm laser is portable and can be used chairside in a few seconds per site, and tulsi extract is cheap and widely available in India. The combination is therefore practical in general practice, provided its effect is confirmed in larger trials. The gel alone gave less benefit, mainly in bleeding and gingival inflammation, and may be suited to sites where a laser is not available.

The added chairside time is small. Irradiation took 10 s per site, and gel placement and a periodontal dressing added a few minutes per quadrant. The main cost is the laser unit itself, which is also used for other soft-tissue procedures. The gel is made from widely available ingredients and could be produced at low cost if a standardised formulation is developed. Neither adjunct replaces thorough SRP and patient plaque control, which produced large improvements on their own in Group 1.

4.7 Limitations

The sample was small (10 per group) and powered only for PPD, so smaller differences in other parameters, including CAL, may have been missed.

Four of five parameters were imbalanced at baseline.

There was no laser-only group, so the separate effects of laser and gel cannot be estimated.

Follow-up lasted only 45 days, which is too short to assess attachment stability or recurrence.

No microbiological or biochemical outcomes (such as crevicular cytokines, MMPs or oxidative-stress markers) were measured, so the proposed mechanisms remain untested.

Probing was manual and recorded to the nearest millimetre, and gingival recession was not recorded separately.

The operator and patients could not be blinded to treatment.
This was a single-centre study in systemically healthy adults aged 25–50 years, so the results may not apply to smokers, people with diabetes or older patients.
Patient-reported outcomes such as post-operative pain, sensitivity and the taste of the gel were not recorded.
Only one concentration of gel and one set of laser parameters were tested.

4.8 Future Directions

Larger multicentre trials with an a priori sample-size calculation and a factorial design (SRP; SRP + gel; SRP + laser; SRP + laser + gel) are needed. They should report outcomes at the patient level, adjust for baseline values and follow patients for at least 6–12 months. Pocket-closure rates (PPD ≤4 mm without bleeding) should be reported. Subgingival microbiology and crevicular biomarkers such as IL-1β, TNF-α, MMP-8 and total antioxidant capacity would test the proposed mechanisms. Formulation work on the gel's viscosity, mucoadhesion and release profile could improve its retention in the pocket.

5. Conclusion

Within the limits of this small, short-term trial, SRP alone, SRP with 4% Ocimum sanctum gel and SRP with gel plus 940 nm diode laser all improved the clinical signs of chronic periodontitis. The combination of diode laser and Ocimum sanctum gel gave the greatest reductions in gingival inflammation, bleeding and pocket depth at 45 days. It did not give greater clinical attachment gain. The gel alone added a modest anti-inflammatory benefit but no extra pocket reduction. Ocimum sanctum gel is inexpensive and readily available, and with diode laser it is a promising adjunct to non-surgical periodontal therapy. Larger trials with a laser-only arm and longer follow-up are needed to confirm these findings.

- **Declarations**
  Ethics approval and consent: Approved by the Institutional Ethics Committee, Drs. Sudha and Nageswara Rao Siddhartha Institute of Dental Sciences. Written informed consent was obtained from all participants.

- **Funding**: This research received no specific grant from any funding agency in the public, commercial or not-for-profit sectors.

- **Conflicts Of Interest:** The authors declare no conflicts of interest.

REFERENCES

1. Kinane DF, Stathopoulou PG, Papapanou PN. Periodontal diseases. Nat Rev Dis Primers. 2017;3:17038. doi:10.1038/nrdp.2017.38
2. Papapanou PN, Sanz M, Buduneli N, Dietrich T, Feres M, Fine DH, et al. Periodontitis: consensus report of workgroup 2 of the 2017 World Workshop on the Classification of Periodontal and Peri-Implant Diseases and Conditions. J Periodontol. 2018;89 Suppl 1:S173-82. doi:10.1002/JPER.17-0721
3. Cobb CM. Clinical significance of non-surgical periodontal therapy: an evidence-based perspective of scaling and root planing. J Clin Periodontol. 2002;29 Suppl 2:6-16. PMID:12010523
4. Rams TE, Slots J. Local delivery of antimicrobial agents in the periodontal pocket. Periodontol 2000. 1996;10:139-59. PMID:9567941
5. Goodson JM, Haffajee A, Socransky SS. Periodontal therapy by local delivery of tetracycline. J Clin Periodontol. 1979;6(2):83-92. PMID:379050
6. Cohen MM. Tulsi – Ocimum sanctum: a herb for all reasons. J Ayurveda Integr Med. 2014;5(4):251-9. doi:10.4103/0975-9476.146554
7. Mallikarjun S, Rao A, Rajesh G, Shenoy R, Pai M. Antimicrobial efficacy of Tulsi leaf (Ocimum sanctum) extract on periodontal pathogens: an in vitro study. J Indian Soc Periodontol. 2016;20(2):145-50. PMID:27143825
8. Hosadurga RR, Rao SN, Edavanputhalath R, Jose J, Rompicharla NC, Shakil M, et al. Evaluation of the efficacy of 2% Ocimum sanctum gel in the treatment of experimental periodontitis. Int J Pharm Investig. 2015;5(1):35-42. doi:10.4103/2230-973X.147231
9. Moritz A, Schoop U, Goharkhay K, Schauer P, Doertbudak O, Wernisch J, et al. Treatment of periodontal pockets with

a diode laser. Lasers Surg Med. 1998;22(5):302-11. PMID:9671997
10. Aoki A, Mizutani K, Schwarz F, Sculean A, Yukna RA, Takasaki AA, et al. Periodontal and peri-implant wound healing following laser therapy. Periodontol 2000. 2015;68(1):217-69. doi:10.1111/prd.12080
11. Sgolastra F, Severino M, Gatto R, Monaco A. Effectiveness of diode laser as adjunctive therapy to scaling root planning in the treatment of chronic periodontitis: a meta-analysis. Lasers Med Sci. 2013;28(5):1393-402. PMID:22895576
12. Dervisbegovic S, Lettner S, Tur D, Laky M, Georgopoulos A, Moritz A, et al. Adjunctive low-level laser therapy in periodontal treatment – a randomized clinical split-mouth trial. Clin Oral Investig. 2025;29(5):273. doi:10.1007/s00784-025-06289-2
13. Ganvir MN, Parwani SR, Chaudhary DS, Parwani R, Dadlani H, Vikey AK, et al. Comparative evaluation of Azadirachta indica (neem) chip and soft tissue diode lasers as a supplement to phase I periodontal therapy in localized chronic moderate periodontitis: a randomized controlled clinical trial. Int J Dent. 2022;2022:6109040. doi:10.1155/2022/6109040
14. Silness J, Löe H. Periodontal disease in pregnancy. II. Correlation between oral hygiene and periodontal condition. Acta Odontol Scand. 1964;22:121-35. PMID:14158464
15. Löe H, Silness J. Periodontal disease in pregnancy. I. Prevalence and severity. Acta Odontol Scand. 1963;21:533-51. PMID:14121956
16. Mombelli A, van Oosten MA, Schurch E Jr, Land NP. The microbiota associated with successful or failing osseointegrated titanium implants. Oral Microbiol Immunol. 1987;2(4):145-51. PMID:3507627
17. Thomas R, Arya K, Shah R, Pooja N. Evaluation of efficacy of 4% Ocimum sanctum gel in the management of chronic periodontitis. J Interdiscip Dent. 2023;13(3):128-33.
18. Deepika BA, Ramamurthy J. Effect of Ocimum sanctum L as LDD in periodontal therapy. Bioinformation. 2023;19(5):590-4. doi:10.6026/97320630019590
19. Rahalkar A, Kumathalli K, Kumar R. Determination of efficacy of curcumin and Tulsi extracts as local drugs in periodontal pocket reduction: a clinical and microbiological study. J Indian Soc Periodontol. 2021;25(3):197-202. doi:10.4103/jisp.jisp_158_20
20. Agrawal A, Sharma AR, Rathod V, Bhatnagar A, Amol Khale P, Tidke P, et al. Assessment of the efficiency of tulsi extract as a locally administered medication agent and its comparison with curcumin in the treatment of periodontal pockets. Cureus. 2024;16(2):e54619. doi:10.7759/cureus.54619
21. Gupta D, Bhaskar DJ, Gupta RK, Karim B, Jain A, Singh R, et al. A randomized controlled clinical trial of Ocimum sanctum and chlorhexidine mouthwash on dental plaque and gingival inflammation. J Ayurveda Integr Med. 2014;5(2):109-16. PMID:24948862
22. Hosamane M, Acharya AB, Vij C, Trivedi D, Setty SB, Thakur SL. Evaluation of holy basil mouthwash as an adjunctive plaque control agent in a four day plaque regrowth model. J Clin Exp Dent. 2014;6(5):e491-6. PMID:25674314
23. Dukić W, Bago I, Aurer A, Roguljic M. Clinical effectiveness of diode laser therapy as an adjunct to non-surgical periodontal treatment: a randomized clinical study. J Periodontol. 2013;84(8):1111-7. PMID:23075433
24. Nammour S, El Mobadder M, Maalouf E, Namour M, Namour A, Rey G, et al. Clinical evaluation of diode (980 nm) laser-assisted nonsurgical periodontal pocket therapy: a randomized comparative clinical trial and bacteriological study. Photobiomodul Photomed Laser Surg. 2021;39(1):10-22. doi:10.1089/photob.2020.4818
25. Matarese G, Ramaglia L, Cicciù M, Cordasco G, Isola G. The effects of diode laser therapy as an adjunct to scaling and root planing in the treatment of aggressive periodontitis: a 1-year randomized controlled clinical trial. Photomed Laser Surg. 2017;35(12):702-9. doi:10.1089/pho.2017.4288
26. Kadhim Salman F, Al-Ameri LMH. Effectiveness of the dual wavelength diode laser as an adjunct to non-surgical treatment in treating periodontal pocket in periodontitis patients: a randomized clinical study. Lasers Med Sci. 2025;40(1):82. doi:10.1007/s10103-025-04344-8
27. Anwar SK, Hafez AM, Roshdy YS. Clinical and microbiological efficacy of intra-pocket application of diode laser in grade C periodontitis: a randomized controlled clinical trial. BMC Oral Health. 2024;24(1):270. doi:10.1186/s12903-024-04031-0
28. Caruso U, Nastri L, Piccolomini R, d'Ercole S, Mazza C, Guida L. Use of diode laser 980 nm as adjunctive therapy in the treatment of chronic periodontitis. A randomized controlled clinical trial. New Microbiol. 2008;31(4):513-8. PMID:19123307
29. Sayar F, Hashemi S, Chiniforush N, Seyed Jafari E, Jandaghi A. Effects of diode and erbium lasers as an adjunct to scaling and root planing on clinical and immunological parameters in non-surgical periodontal treatment: a split-mouth randomized controlled clinical trial. Lasers Med Sci. 2022;37(7):3021-30. doi:10.1007/s10103-022-03596-y