Research Article

Clinical, Radiographic, And Prosthetic Evaluation Of Syncrystallized Basal Implants In Deficient Alveolar Ridges: A 12-Month Prospective Pilot Study

Sumit Bhatt[1]*, Hoti Lal Gupta[2]

[1]Assistant Professor & PhD Scholar, Department of Oral & Maxillofacial Surgery, Rajasthan Dental College & Hospital, Nirwan University, Jaipur, Rajasthan, India sumittbhatt22@gmail.com
[2]Principal & Dean, Professor & Head, Department of Periodontology & Oral Implantology, Rajasthan Dental College & Hospital, Nirwan University, Jaipur, Rajasthan, India hlgupta7@yahoo.co.in

Abstract

Background: Implant-supported prosthetic rehabilitation is a predictable treatment option for replacing missing teeth; however, its long-term success depends on implant stability, peri-implant tissue health, marginal bone preservation, prosthetic integrity, and patient satisfaction. Aim: To evaluate the clinical, radiographic, prosthetic, and patient-reported outcomes of implant-supported rehabilitation over a 12-month follow-up period. Materials and Methods: A prospective clinical investigation was conducted at various dental hospitals in Uttarakhand from January 2025 to April 2026. 50 patients requiring implant-supported rehabilitation were enrolled. Clinical assessments were performed at immediate loading and at 3, 6, and 12 months, including implant mobility, peri-implant plaque index (PI), and modified gingival index (MGI). Radiographic evaluation at 12 months assessed marginal bone loss (MBL), cortical anchorage, and peri-implant radiolucency. Prosthetic complications, implant survival, composite functional success, and patient satisfaction regarding comfort, esthetics, chewing efficiency, and overall satisfaction were also evaluated. Statistical analysis was performed using international Business Machines (IBM SPSS) Statistics Version 27.0. Results: 47 patients (94.0%) completed the 12-month follow-up. Implant mobility remained minimal, with the majority of implants demonstrating no detectable mobility throughout the observation period. Mean PI and MGI scores showed progressive reductions from immediate loading to 12 months, indicating improved plaque control and peri-implant soft-tissue conditions. At the final assessment, 78.7% of patients exhibited MBL of 0.5 mm or less, while 95.7% demonstrated bone loss not exceeding 1.0 mm. Satisfactory cortical anchorage and absence of peri-implant radiolucency were observed in 97.9% of patients. Major prosthetic complications were absent in 93.6% of cases. Implant survival was 97.9%, while composite functional success was achieved in 93.6% of assessed patients. Patient-reported scores were favourable across all domains, with overall satisfaction receiving the highest mean rating. Conclusion: Implant-supported rehabilitation demonstrated favourable clinical stability, peri-implant tissue health, radiographic outcomes, prosthetic performance, and patient satisfaction over 12 months. The findings support the effectiveness of implant-supported prostheses in restoring function and esthetics, although longer-term follow-up is necessary to establish durability and predictability of outcomes.

Keywords: Cortical anchorage, Dental implants, Implant survival, Marginal bone loss, Patient satisfaction, Peri-implant health, Prosthetic rehabilitation

1. Introduction

The loss of natural teeth can adversely affect mastication, speech, facial appearance, and overall quality of life. Replacement of missing teeth is therefore important not only for restoring oral function but also for improving esthetics, comfort, and psychosocial well-being. Dental implants have emerged as a widely accepted treatment modality for replacing missing teeth, providing stable support for prosthetic restorations and offering an alternative to conventional tooth-supported or tissue-supported prostheses. Advances in implant materials, surgical techniques, and prosthetic planning have contributed to the increasing use of implant-supported rehabilitation in partially and completely edentulous patients [1].

The clinical success of implant therapy depends on the establishment and maintenance of osseointegration, adequate primary stability, appropriate implant positioning, favourable bone conditions, and effective prosthetic loading. Although successful implant placement is an important milestone, sustained clinical performance requires continued stability of the implant and surrounding tissues after restoration. Implant survival alone may not adequately reflect

treatment success, as biological complications, mechanical problems, functional limitations, and patient dissatisfaction may occur even when an implant remains in situ [2].

Peri-implant soft-tissue health is a major determinant of the long-term maintenance of dental implants. Plaque accumulation around implant surfaces may initiate inflammatory changes in the peri-implant mucosa, potentially leading to tissue breakdown and progressive bone destruction if appropriate preventive measures are not implemented. Regular assessment of plaque accumulation and gingival inflammation is therefore essential for monitoring tissue health and identifying early signs of peri-implant disease. Clinical indices, including the plaque index (PI) and gingival index (GI), provide useful information regarding oral hygiene status and the response of peri-implant tissues to treatment and maintenance protocols [3].

Radiographic evaluation is equally important for assessing the supporting bone and the integrity of the implant–bone interface. Marginal bone remodelling may occur following implant placement and functional loading, but excessive bone loss can compromise the long-term prognosis of implant therapy. Evaluation of marginal bone levels, cortical anchorage, and peri-implant radiolucency helps identify changes in the supporting structures and provides objective information regarding implant stability. Serial or follow-up radiographic assessments are valuable in detecting unfavourable bone changes and evaluating the maintenance of peri-implant integrity over time [4].

Prosthetic performance represents another important aspect of implant rehabilitation, as the restoration must withstand functional forces while maintaining comfort, esthetics, and mechanical integrity. Complications such as screw loosening, occlusal discrepancies, framework fracture, and esthetic or phonetic problems may necessitate additional treatment and adversely affect patient satisfaction. Appropriate prosthetic design, accurate occlusal adjustment, proper maintenance, and periodic clinical review are essential for reducing complications and ensuring satisfactory functional performance. Consequently, prosthetic complications should be considered alongside biological and radiographic parameters when evaluating implant treatment outcomes [5].

Patient-reported outcomes have become increasingly relevant in contemporary implant dentistry because the effectiveness of rehabilitation should also be judged from the patient's perspective. Improvements in chewing ability, comfort, esthetic appearance, speech, and confidence are important indicators of perceived treatment benefit [6]. Patient satisfaction may not always correspond directly with clinical findings; therefore, incorporating subjective assessments with objective clinical and radiographic measurements provides a more comprehensive understanding of rehabilitation outcomes. Evaluation of these parameters helps determine whether implant-supported restorations fulfil patients' functional and esthetic expectations [7].

Despite the high predictability of implant therapy, variations in patient characteristics, anatomical conditions, oral hygiene practices, prosthetic designs, and maintenance compliance may influence clinical outcomes. Follow-up assessment is particularly important for identifying early changes in implant mobility, peri-implant tissue condition, bone levels, and prosthetic integrity. A comprehensive evaluation incorporating implant survival, biological health, radiographic stability, prosthetic complications, and patient satisfaction can provide a more meaningful measure of treatment effectiveness than relying on a single outcome parameter [8,9].

Therefore, the present study was undertaken to comprehensively evaluate the clinical, radiographic, prosthetic, and patient-reported outcomes of implant-supported rehabilitation over a 12-month follow-up period. The assessment included implant mobility, peri-implant plaque accumulation, gingival health, marginal bone loss (MBL), cortical anchorage, peri-implant radiolucency, prosthetic complications, implant survival, composite functional success, and patient satisfaction. This integrated assessment was intended to provide an overall understanding of implant performance and the effectiveness of implant-supported rehabilitation in restoring oral function, maintaining peri-implant health, and achieving satisfactory patient-reported outcomes.

2. Materials And Methods

2.1 Study Design And Setting

The present study was conducted as a prospective clinical investigation at various dental hospitals in Uttarakhand from January 2025 to April 2026 to evaluate the clinical, radiographic, prosthetic, and patient-reported outcomes of implant-

supported rehabilitation over a 12-month follow-up period. The study assessed implant stability, peri-implant soft-tissue health, MBL, cortical anchorage, radiographic integrity, prosthetic complications, patient satisfaction, implant survival, and overall functional success following treatment.

2.2 Study Population And Sample Size

A total of 50 patients requiring implant-supported rehabilitation were recruited and treated according to the predetermined clinical protocol. The enrolled participants were followed up at immediate loading and at 3, 6, and 12 months after treatment. The study population comprised patients aged 24–75 years, with a mean age of 52.4 ± 10.2 years. Both male and female patients were included.

2.3 Patient Selection Criteria

Patients were selected based on clinical examination, treatment requirements, and suitability for implant-supported rehabilitation.

2.3.1 Inclusion Criteria:

Patients requiring implant-supported prosthetic rehabilitation
Patients with adequate clinical and radiographic bone support for implant placement
Patients with satisfactory oral hygiene or the ability to maintain oral hygiene following implant treatment
Patients willing to undergo the prescribed follow-up examinations
Patients providing informed consent for participation in the study

2.3.2 Exclusion Criteria:

Patients with uncontrolled systemic conditions that could adversely affect osseointegration or wound healing
Patients with active oral infections or untreated periodontal disease at the proposed implant site
Patients with inadequate bone volume for implant placement without additional augmentation procedures, where augmentation was not part of the study protocol
Patients unable or unwilling to comply with the scheduled follow-up visits
Patients with contraindications to implant surgery or the planned prosthetic rehabilitation

2.4 Demographic, Clinical, Radiographic Assessment, Implant Placement And Prosthetic Rehabilitation

Baseline demographic characteristics, including age and sex, were recorded for all participants. The distribution of treatment sites was documented according to maxillary, mandibular, or simultaneous involvement of both arches. A comprehensive preoperative clinical and radiographic assessment was performed to evaluate the existing dentition, periodontal status, residual alveolar ridge conditions, presence of infection, extent of alveolar bone resorption, and suitability for full-mouth implant-supported rehabilitation. The initial panoramic radiograph was examined to identify multiple infected teeth and compromised alveolar ridge conditions [Figure 1]. Following the initial assessment, extraction of the remaining teeth was performed. A subsequent intraoral examination was conducted to evaluate the edentulous arches and the condition of the residual alveolar ridges [Figures 2 and 3]. Further clinical and anatomical evaluation was undertaken to determine the appropriate implant positions and available support for full-mouth rehabilitation.

Following completion of the diagnostic assessment and treatment planning, basal implants were surgically placed in the maxillary and mandibular arches using a basal implant kit (Redice Company) and a physiodespenser (Marathon Company), in accordance with the anatomical requirements and recommended clinical protocols [Figure 4]. Implant positioning was planned to ensure optimal distribution and adequate support for the proposed full-mouth prosthetic rehabilitation. Subsequently, syncrystallization was performed using a titanium syncrystallizer (GenXT, Switzerland) to stabilize the implants by means of an intraoral metallic framework. The procedure was carried out separately in the maxillary and mandibular arches using a 2-mm titanium wire framework, with the respective clinical views documented [Figures 5, 6, and 7]. A combined intraoral clinical view was obtained to demonstrate the completed syncrystallization framework connecting the implants in both arches [Figure 8]. Thereafter, welding was performed to achieve rigid stabilization of the implant assembly.

Once the welding and stabilization procedures were completed, digital scanning was performed to record the implant positions and the welded framework, thereby facilitating accurate prosthetic planning and fabrication [Figure 9]. The

definitive full-mouth prosthesis was fabricated based on the recorded digital information and subsequently inserted [Figure 10]. Extraoral facial profile photographs were obtained before and after prosthesis insertion to document changes in facial appearance and restoration of facial support [Figure 11]. A postoperative panoramic radiograph was obtained to evaluate the placement and distribution of basal implants in both arches following rehabilitation [Figure 12]. Finally, serial panoramic radiographic evaluations were performed at 3, 6, and 12 months to monitor the implant-supported rehabilitation and assess the radiographic status throughout the follow-up period [Figure 13].

3. Clinical Evaluation

3.1 Implant Mobility

Implant mobility was evaluated clinically immediately after surgery and at 3, 6, and 12 months postoperatively using the Modified Miller Mobility Index (MMMI). The assessment was performed by applying labiolingual forces to the implant using two rigid instruments to detect any movement. The presence of mobility and pain or tenderness on percussion were also assessed. Each implant was assigned a mobility score ranging from 0 to 3 according to the degree of movement observed, as follows:

- Score 0: No detectable mobility
- Score 1: Mobility of up to 1 mm
- Score 2: Mobility greater than 1 mm and up to 2 mm
- Score 3: Mobility exceeding 2 mm and/or rotational or vertical (depressive) movement.

The scores were recorded at each follow-up visit to monitor implant stability and evaluate changes in mobility over the study period.

3.2 PI

Peri-implant plaque accumulation was assessed using the PI described by Silness and Löe (1964) immediately after loading and at 3, 6, and 12 months postoperatively. The index was used to evaluate plaque deposition on the peri-implant surfaces. Plaque accumulation was scored according to the following criteria:

- Score 0: No plaque accumulation
- Score 1: A thin film of plaque detectable only by passing a probe along the implant surface
- Score 2: Moderate plaque accumulation visible to the naked eye
- Score 3: Abundant plaque accumulation

The scores were recorded at each follow-up visit to assess oral hygiene status and changes in peri-implant plaque accumulation over time

3.3 MGI

Peri-implant soft-tissue health was evaluated using the Modified Gingival Index (MGI) described by Löe and Silness (1963) immediately after loading and at 3, 6, and 12 months postoperatively. The index was used to assess gingival inflammation and changes in the peri-implant mucosal condition. Gingival health was graded according to the following scoring criteria:

- Score 0: Normal gingiva with no signs of inflammation
- Score 1: Mild inflammation characterized by slight changes in colour and mild oedema, without bleeding on probing (BOP)
- Score 2: Moderate inflammation characterized by redness, oedema, and a glazed appearance, with BOP
- Score 3: Severe inflammation characterized by marked redness and oedema, ulceration, and a tendency towards spontaneous bleeding

The scores were recorded at each follow-up visit to monitor changes in peri-implant soft-tissue health over the study period.

4. Radiographic Evaluation

4.1 MBL

It was evaluated radiographically at the 12-month follow-up using cone-beam computed tomography (CBCT), panaromic radiography and/or radiovisiography (RVG), as applicable. The mesial and distal peri-implant bone levels were assessed, and the mean MBL was categorized into predefined scoring intervals as follows:

- Score 0: 0–0.5 mm
- Score 1: 0.6–1.0 mm
- Score 2: 1.1–2.0 mm
-

The distribution of patients across the respective bone-loss categories was recorded to determine the extent of marginal bone changes around the implants.

4.2 Cortical Anchorage

It was evaluated at the 12-month follow-up based on the radiographic and clinical evidence of cortical engagement and implant stability. The findings were classified as satisfactory or questionable/unsatisfactory according to the predefined assessment criteria.

4.3 Peri-Implant Radiolucency

Radiographs obtained at the 12-month assessment were examined for the presence or absence of radiolucent areas surrounding the implants. Peri-implant radiolucency was recorded as an indicator of radiographic integrity and possible compromised implant-bone interface.

5. Assessment Of Prosthetic Complications

Prosthetic outcomes were evaluated at the 12-month follow-up. Complications were documented based on clinical examination and patient-reported concerns. The assessment included occlusal disharmony requiring adjustment, screw loosening, framework fracture, and esthetic or phonetic concerns. Patients without major prosthesis-related complications were classified accordingly. Each complication was recorded separately to describe the distribution of prosthetic events.

5.1 Patient-Reported Outcome Measures

Patient satisfaction and perceived functional performance were assessed at 12 months using a five-point rating scale. The following domains were evaluated:

- Comfort
- Esthetic appearance
- Chewing efficiency
- Overall satisfaction
-

Responses were recorded and summarized using mean scores, standard deviations (SD), standard errors (SE), and observed score ranges. Higher scores indicated more favourable patient-reported outcomes.

5.2 Follow-Up And Retention

Participants were evaluated at immediate loading and at 3, 6, and 12 months. The number of patients attending each follow-up visit was documented, and the retention rate was calculated relative to the original sample of 50 participants. Patients who did not attend the final follow-up were considered lost to follow-up, and their outcome status was not assumed unless documented independently.

5.3 Implant Survival And Composite Functional Success

Implant survival was evaluated at the 12-month follow-up based on implant retention and documented failure status. Implants that remained in situ without confirmed failure were classified as surviving. The survival rate was calculated among patients with known implant status, while patients lost to follow-up were considered to have unknown survival status.Composite functional success was assessed using the predefined clinical, radiographic, and prosthetic outcome criteria. Patients fulfilling all applicable success criteria were classified as having composite functional success. Implant survival and composite functional success were evaluated separately to distinguish implant retention from satisfactory overall clinical and functional performance.

6. Study Hypotheses

6.1 Overall Hypothesis

- **Null Hypothesis (H_0)**: There is no statistically significant difference in the functional outcomes of basal implants with syncrystallization compared with those of conventional implant approaches reported in the literature for the rehabilitation of deficient alveolar ridges.

- **Alternative Hypothesis (H_1):** Basal implants with syncrystallization demonstrate statistically significantly better functional outcomes than conventional implant approaches reported in the literature for the rehabilitation of deficient alveolar ridges.

6.2 Clinical Outcomes (Implant Stability, Peri-Implant Soft-Tissue Health, And Patient Satisfaction)

- **Null Hypothesis (H_{01}):** Basal implants with syncrystallization do not result in statistically significant improvements in implant stability, peri-implant soft-tissue health, or patient satisfaction over the follow-up period.

- **Alternative Hypothesis (H_{11}):** Basal implants with syncrystallization result in statistically significant improvements in implant stability, peri-implant soft-tissue health, and patient satisfaction over the follow-up period.

6.3 Radiographic Outcomes (Cortical Anchorage, Marginal Bone Levels, And Peri-Implant Radiolucency)

- **Null Hypothesis (H_{02}):** Basal implants with syncrystallization do not demonstrate statistically significant differences in cortical anchorage, marginal bone preservation, or peri-implant radiolucency compared with conventional implant approaches.

- **Alternative Hypothesis (H_{12}):** Basal implants with syncrystallization demonstrate significantly better cortical anchorage, greater marginal bone preservation, and a lower incidence of peri-implant radiolucency than conventional implant approaches.

6.3 Prosthetic Outcomes (Occlusal Harmony, Aesthetics, And Functional Stability)

- **Null Hypothesis (H_{03}):** Basal implants with syncrystallization do not result in statistically significant improvements in prosthetic outcomes, including occlusal harmony, aesthetics, and functional stability.

- **Alternative Hypothesis (H_{13}):** Basal implants with syncrystallization result in statistically significant improvements in prosthetic outcomes, including occlusal harmony, aesthetics, and functional stability.

6.4 Comparison With Conventional Implant Approaches (Literature-Based Benchmarks)

- **Null Hypothesis (H_{04}):** The functional outcomes of basal implants with syncrystallization do not differ significantly from those of conventional implant approaches reported in the literature.

- **Alternative Hypothesis (H_{14})**: The functional outcomes of basal implants with syncrystallization are statistically significantly superior to those of conventional implant approaches reported in the literature.

6.5 Effectiveness Of The Syncrystallization Technique

- **Null Hypothesis (H_{05}):** The syncrystallization technique does not have a statistically significant effect on immediate rehabilitation success or the long-term clinical and functional outcomes of basal implants.

- **Alternative Hypothesis (H_{15}):** The syncrystallization technique significantly enhances immediate rehabilitation success and the long-term clinical and functional outcomes of basal implants.

7. Statistical Analysis

The collected data were entered and analysed using International Business Machines (IBM) Statistical Package for the Social Sciences (SPSS) Statistics for Windows, Version 27.0 (IBM Corp., Armonk, NY, USA). Continuous variables, including age, PI, MGI, and patient-reported outcome scores, were summarized using means and SD. Categorical variables, including sex, treatment region, implant mobility scores, MBL categories, cortical anchorage, radiolucency, prosthetic complications, implant survival, and functional success, were expressed as frequencies and percentages. Changes in clinical indices across follow-up intervals were summarized descriptively. Follow-up completion, implant survival, and composite functional success rates were calculated using their respective denominators. Statistical significance was considered at a probability (p)-value of less than 0.05, where inferential testing was applicable.

- **Ethical Considerations**

The study was conducted in accordance with the ethical principles governing clinical research involving human participants. Institutional ethical approval was obtained from the Ethics Committee under approval number NUJ/RDC/2025 before commencement of the study. Written informed consent was obtained from all participants, and patient confidentiality was maintained throughout data collection, analysis, and reporting.



Figure 1: Preoperative panoramic radiograph demonstrating multiple infected teeth and severely resorbed alveolar ridges in both maxillary and mandibular arches

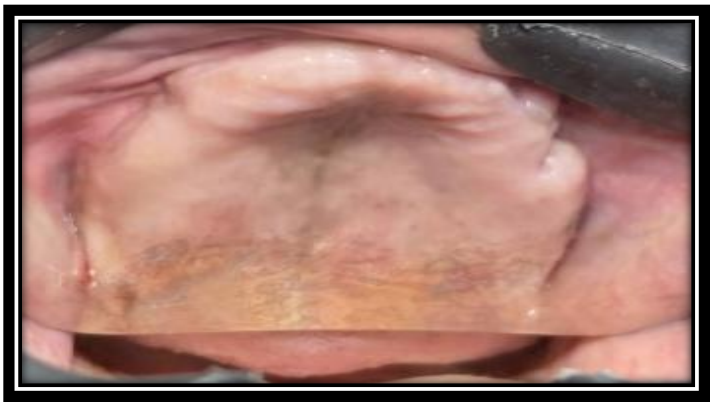

Figure 2:Intraoral clinical view of the maxillary arch following extraction of the remaining teeth, demonstrating the residual alveolar ridge before implant placement



Figure 3: Intraoral clinical view of the mandibular arch following extraction, showing the available residual alveolar ridge for implant-supported rehabilitation.



Figure 4: Intraoperative intraoral view demonstrating the placement of basal implants in the maxillary arch for full-arch implant-supported rehabilitation



Figure 5: Clinical view demonstrating syncrystallization of the basal implants in the maxillary arch using an intraoral metallic framework



Figure 6: Clinical view demonstrating syncrystallization of the basal implants in the mandibular arch through intraoral framework (2 mm titanium wire) stabilization



Figure 7: Clinical view demonstrating syncrystallization of the basal implants in the mandibular arch through intraoral framework (2 mm titanium wire) stabilization



Figure 8: Combined intraoral view demonstrating the completed syncrystallization framework (2 mm titanium wire)in both maxillary and mandibular arches

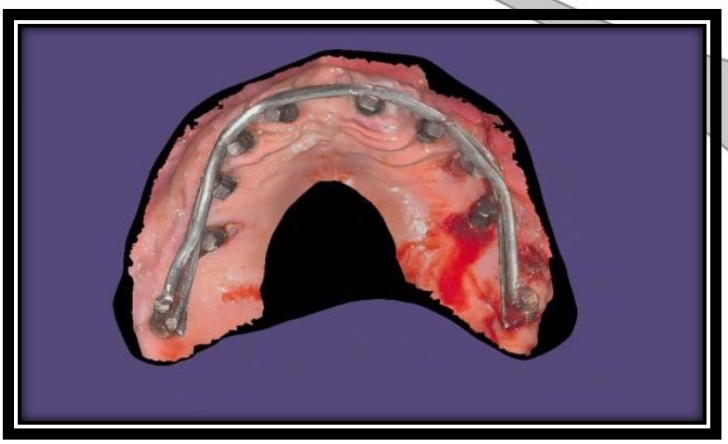

Figure 9: Digital scanning of the implant positions and welded framework to facilitate accurate prosthetic planning and fabrication



Figure 10:Intraoral view of completed full-mouth prosthetic rehabilitation



Figure 11: Extraoral facial profile before and after prosthesis insertion



Figure 12: Postoperative panoramic radiograph demonstrating the placement and distribution of basal implants in both arches following implant-supported rehabilitation

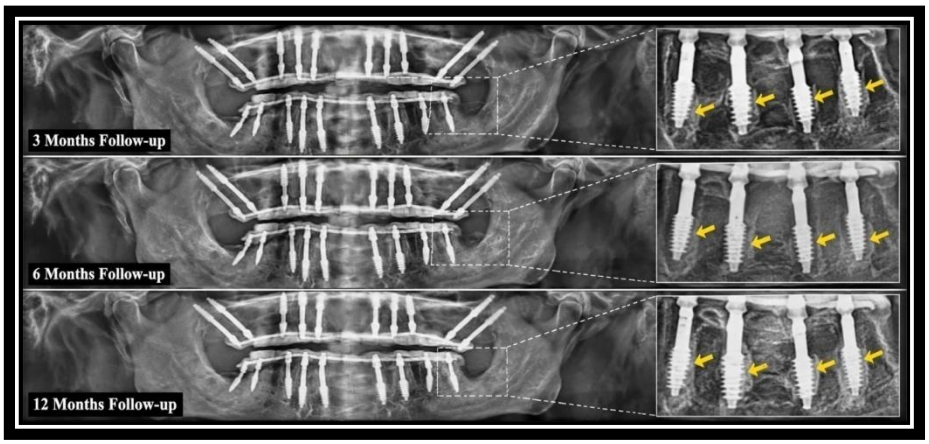

Figure 13: Serial panoramic radiographic assessments demonstrating the status of the full-mouth basal implant-supported rehabilitation at 3-, 6-, and 12-month follow-up intervals

8. Results

Table 1 presents the patient follow-up and retention profile throughout the study period. A total of 50 patients were initially recruited and received the assigned treatment. Follow-up assessments were completed by 49 patients at 3 months (98.0%), 48 patients at 6 months (96.0%), and 47 patients at 12 months (94.0%). Thus, three patients (6.0%) were lost to follow-up by the end of the study, while the remaining participants completed the final assessment.

Table 1: Patient recruitment and follow-up

Stage	Patients (n)	% of enrolled
Enrolled and treated	50	100.0
Completed 3-month assessment	49	98.0
Completed 6-month assessment	48	96.0
Completed 12-month assessment	47	94.0

Table 2 summarizes the baseline demographic and clinical characteristics of the study participants. The mean age of the 50 enrolled patients was 52.4 ± 10.2 years, with an age range of 24–75 years. The study population comprised 27 males (54.0%) and 23 females (46.0%), indicating a slightly higher proportion of male participants. Regarding the anatomical site of treatment, the mandible was the most commonly involved region, accounting for 24 cases (48.0%), followed by the maxilla in 21 cases (42.0%). Both arches were involved in 5 patients (10.0%). Thus, mandibular involvement represented the largest proportion of the treated cases.

Table 2:Baseline characteristics

Variable	Category	n (%) / Mean ± SD
Age, years	Mean ± SD	52.4 ± 10.2
Age, years	Range	24–75
Sex	Male	27 (54.0%)
Sex	Female	23 (46.0%)
Ridge / treatment region	Maxilla	21 (42.0%)
Ridge / treatment region	Mandible	24 (48.0%)
Ridge / treatment region	Both arches	5 (10.0%)

Table 3 illustrates the distribution of patients according to the MMMI at immediate loading and subsequent follow-up examinations at 3, 6, and 12 months. At baseline, 48 patients (96.0%) exhibited a mobility score of 0, indicating the absence of detectable mobility, while 2 patients (4.0%) presented with a score of 1. At the 3-month evaluation, 48 of the 49 patients assessed (98.0%) maintained a score of 0, whereas 1 patient (2.0%) demonstrated a score of 1. Similarly, at 6 months, 47 patients (97.9%) had a score of 0 and 1 patient (2.1%) had a score of 1. At the final 12-month examination, 46 patients (97.9%) showed no detectable mobility, while 1 patient (2.1%) exhibited a score of 1. No instances of mobility scores 2 or 3 were recorded at any assessment point. Overall, the findings indicate that the majority of patients maintained stable implant mobility status throughout the follow-up period

Table 3: MMMI at different visits

Visit	Score 0 n (%)	Score 1 n (%)	Score 2 n (%)	Score 3 n (%)	Total
Immediate loading	48 (96.0)	2 (4.0)	0 (0.0)	0 (0.0)	50
3 months	48 (98.0)	1 (2.0)	0 (0.0)	0 (0.0)	49
6 months	47 (97.9)	1 (2.1)	0 (0.0)	0 (0.0)	48
12 months	46 (97.9)	1 (2.1)	0 (0.0)	0 (0.0)	47

Table 4 depicts the changes in PI scores recorded at immediate loading and subsequent follow-up visits at 3, 6, and 12 months to assess peri-implant plaque accumulation. The initial mean PI score was 0.86 ± 0.47 in the study population of 50 patients. At the 3-month evaluation, the mean score decreased to 0.72 ± 0.44 among 49 patients. A further decline was observed at 6 months, with a mean value of 0.64 ± 0.42. At the final 12-month assessment, the mean score reached 0.58 ± 0.39. Overall, the findings indicate a gradual reduction in plaque accumulation throughout the observation period, with the lowest mean PI recorded at the end of 12 months.

Table 4: PI at different follow-up intervals

Assessment time	n assessed	Mean	SD	Mean change from immediate loading	Reduction (%)
Immediate loading	50	0.86	0.47	—	—
3 months	49	0.72	0.44	−0.14	16.3
6 months	48	0.64	0.42	−0.22	25.6
12 months	47	0.58	0.39	−0.28	32.6

Table 5 illustrates the temporal changes in MGI scores recorded at immediate loading and at 3-, 6-, and 12-month follow-up intervals to evaluate peri-implant gingival health. The initial mean score was 0.80 ± 0.46 among the 50 participants. At the 3-month assessment, the mean value decreased to 0.67 ± 0.43, with a further decline to 0.59 ± 0.40 at 6 months. By the end of the 12-month follow-up, the mean score had reduced to 0.51 ± 0.38. Overall, a consistent downward trend in MGI scores was observed throughout the study period, suggesting a gradual improvement in peri-implant gingival health.

Table 5:MGI at different follow-up intervals

Assessment time	n assessed	Mean	SD	Mean change from immediate loading	Reduction (%)
Immediate loading	50	0.80	0.46	—	—
3 months	49	0.67	0.43	−0.13	16.3
6 months	48	0.59	0.40	−0.21	26.3
12 months	47	0.51	0.38	−0.29	36.3

Table 6 summarizes the distribution of patients according to MBL at the 12-month follow-up. Among the 47 patients evaluated, 37 (78.7%) exhibited bone loss within the 0–0.5 mm range (Score 0). A bone loss of 0.6–1.0 mm (Score 1) was observed in 8 patients (17.0%), whereas 2 patients (4.3%) demonstrated bone loss ranging from 1.1 to 2.0 mm (Score 2). Overall, 45 patients (95.7%) showed MBL not exceeding 1.0 mm, while only a small proportion exhibited bone loss between 1.1 and 2.0 mm. These findings indicate that marginal bone changes remained limited in the majority of patients during the 12-month follow-up period.

Table 6:Assessment of MBL at 12 months

MBL	Average mesial–distal bone loss	Patients (n)	Percentage (%)
Score 0	0–0.5 mm	37	78.7
Score 1	0.6–1.0 mm	8	17.0
Score 2	1.1–2.0 mm	2	4.3
Total	—	47	100.0

Table 7 illustrates the cortical anchorage findings recorded at the 12-month assessment. Of the 47 patients examined, 46 (97.9%) demonstrated satisfactory cortical engagement, while 1 patient (2.1%) showed evidence of compromised or uncertain anchorage. The results indicate that favourable cortical stability was achieved in almost all cases and remained evident at the final follow-up examination.

Table 7:Assessment of cortical anchorage at 12 months

Cortical anchorage status	Patients (n)	Percentage (%)
Satisfactory	46	97.9
Questionable/unsatisfactory	1	2.1
Total	47	100.0

Table 8 summarizes the radiographic findings related to peri-implant radiolucency at the 12-month follow-up. No radiolucent changes were detected around the implants in 46 of the 47 patients examined (97.9%), whereas radiolucency was identified in only 1 patient (2.1%). These observations indicate that peri-implant radiographic integrity was preserved in the majority of cases, reflecting favourable radiological findings at the final assessment.

Table 8:Assessment of peri-implant radiolucency at 12 months

Peri-implant radiolucency status	Patients (n)	Percentage (%)
Absent	46	97.9
Present	1	2.1
Total	47	100.0

Table 9 summarizes the prosthetic complications documented during the 12-month follow-up. Among the 47 patients evaluated, 44 (93.6%) experienced no major prosthesis-related complications. Occlusal discrepancies necessitating clinical adjustment were identified in 2 patients (4.3%), while screw loosening occurred in 1 patient (2.1%). No framework fractures were observed during the assessment period. Additionally, esthetic or phonetic difficulties were reported in 1 patient (2.1%). Overall, the findings indicate a high proportion of favourable prosthetic outcomes, with relatively few complications observed at the end of the 12-month follow-up.

Table 9: Distribution of prosthetic outcomes at 12 months

Prosthetic outcome	Patients (n)	Percentage (%)
No recorded major prosthetic complication	44	93.6
Occlusal disharmony requiring adjustment	2	4.3
Screw loosening	1	2.1
Framework fracture	0	0.0
Esthetic or phonetic concern	1	2.1
Total patients assessed	47	100.0

Table 10 illustrates the patient-reported outcomes relating to comfort, esthetic appearance, chewing ability, and overall satisfaction at the 12-month follow-up. Among the four domains assessed, overall satisfaction achieved the highest mean score (4.30 ± 0.67), followed by esthetic appearance (4.25 ± 0.69). The mean scores for comfort and chewing efficiency were 4.18 ± 0.72 and 4.16 ± 0.74, respectively. The SE across the assessed parameters ranged from 0.098 to 0.108. All four domains recorded mean scores exceeding 4.0 on the five-point rating scale. These findings reflect favourable patient perceptions of the functional and esthetic outcomes, along with a high level of overall satisfaction at the end of the 12-month observation period.

Table 10:Patient satisfaction and function at 12 months

Domain	Mean	SD	SE	Range (Min–Max)
Comfort	4.18	0.72	0.105	1–5
Esthetics	4.25	0.69	0.101	1–5
Chewing efficiency	4.16	0.74	0.108	1–5
Overall satisfaction	4.30	0.67	0.098	1–5

Table 11 summarizes the 12-month follow-up status, implant survival, and overall functional success of the study participants. Of the 50 patients initially enrolled, 47 completed the final evaluation, yielding a follow-up retention rate of 94.0%. Among the patients assessed, 44 (93.6%) fulfilled the predefined criteria for composite functional success. Implant survival was documented in all 47 patients who attended the final follow-up, with 46 (97.9%) demonstrating successful implant retention and 1 (2.1%) experiencing implant failure. However, the survival status of the remaining 3 patients (6.0%) who were unavailable for the final assessment could not be established. Overall, the results demonstrate favourable implant survival and functional outcomes at the 12-month evaluation.

Table 11: 12-month functional success and implant survival summary

Outcome	Numerator / Denominator	Estimate
Completed 12-month assessment	47/50	94.0%
Composite functional success	44/47	93.6%
Patients with known survival status	47/47	100.0%
Implant survival among patients with known status	46/47	97.9%
Confirmed implant failures	1/47	2.1%
Unknown survival status among enrolled patients	3/50	6.0%

9. Discussion

The rehabilitation of edentulous patients using complete-arch fixed implant-supported prostheses has become a predictable treatment modality, offering functional restoration, improved masticatory efficiency, patient satisfaction, and enhanced quality of life. However, the long-term success of these rehabilitations depends on several factors, including implant number, implant distribution, loading protocol, prosthetic retention, implant angulation, material selection, and the occurrence of biological and mechanical complications.

Gaddale et al. (2020) [10] evaluated complications associated with screw-retained and cement-retained implant-supported full-arch restorations through a systematic review and meta-analysis. Their review highlighted the relevance of prosthetic retention design in determining the complication profile of full-arch implant rehabilitations. Screw-retained restorations offer advantages in retrievability and maintenance, whereas cement-retained restorations may present challenges associated with residual cement and peri-implant tissue health. These findings emphasize the importance of selecting an appropriate prosthetic retention mechanism to facilitate maintenance and minimize complications over the long term.

Gallardo et al. (2019) [11] systematically reviewed clinical outcomes of patients rehabilitated with complete-arch fixed implant-supported prostheses according to the timing of prosthetic loading. Their work highlighted the importance of loading protocols in influencing implant survival, prosthetic success, and clinical stability. Immediate loading offers the advantage of reduced treatment duration and early functional rehabilitation; however, careful patient selection, adequate primary implant stability, and appropriate occlusal management remain essential. The findings reinforce that the timing of loading should be determined by clinical and biomechanical considerations rather than convenience alone.

de Luna Gomes et al. (2019) [12] investigated the optimal number of implants required to support complete-arch implant-supported prostheses, with a minimum follow-up period of five years. Their systematic review and meta-analysis addressed the relationship between implant number and long-term clinical outcomes. The selection of an adequate number of implants is critical for distributing occlusal forces, maintaining prosthetic stability, and reducing the risk of biological or mechanical complications. Nevertheless, implant number should be considered alongside arch anatomy, bone availability, prosthesis design, cantilever length, and the patient's functional demands, rather than being regarded as an isolated determinant of success.

DelFabbro et al. (2022) [13] assessed the outcomes of fixed full-arch rehabilitations supported by tilted and axially placed implants. Their systematic review and meta-analysis provided evidence regarding the clinical role of implant angulation in full-arch treatment. Tilted implants may allow the utilization of available bone, facilitate posterior implant placement, and potentially reduce the need for additional augmentation procedures. The strategic placement of tilted implants, when combined with axial implants, may improve prosthetic support and help optimize the distribution of functional forces. These considerations demonstrate the importance of implant positioning and prosthetic biomechanics in treatment planning.

Monteiro et al. (2025) [14] evaluated clinical outcomes of zirconia implants supporting multi-unit and complete-arch prostheses through a systematic review and meta-analysis. Their investigation reflects the growing interest in ceramic implant systems as alternatives to conventional titanium implants, particularly with respect to material properties, tissue response, and aesthetic considerations. The use of zirconia in full-arch rehabilitations requires careful evaluation of implant survival, prosthetic complications, and long-term clinical performance. Material selection should therefore be based on available evidence, clinical indications, and the mechanical demands of the rehabilitated arch.

Francisco et al. (2026) [15] systematically reviewed patient-reported and clinician-reported outcomes and outcome measures associated with maxillary full-arch fixed prostheses supported by different numbers of implants. Their work underscores the importance of evaluating implant rehabilitation beyond conventional clinical parameters such as survival and marginal bone levels. Patient satisfaction, comfort, oral function, aesthetics, treatment-related expectations, and maintenance requirements are equally important in determining the overall effectiveness of full-arch rehabilitation. Incorporating patient-reported outcomes into clinical evaluation provides a more comprehensive understanding of treatment success and supports individualized treatment planning.

Collectively, these studies demonstrate that the clinical success of complete-arch fixed implant-supported prostheses is multifactorial. Prosthetic retention, loading timing, implant number, implant angulation, restorative material, and patient-centred outcomes all contribute to the overall treatment prognosis. A comprehensive treatment approach that integrates biomechanical principles, prosthetic design, biological considerations, and patient expectations is essential for achieving predictable outcomes and maintaining long-term function and satisfaction.

10. Limitations

The present study had certain limitations that should be considered while interpreting the findings. The sample size was relatively small, with only 50 patients enrolled, which may limit the generalizability of the results to a broader population. The follow-up period was restricted to 12 months; therefore, long-term implant stability, marginal bone changes, and prosthetic complications could not be assessed. Additionally, three patients were lost to follow-up, potentially influencing the interpretation of outcomes at the final assessment. Furthermore, the absence of a comparative control group limited the ability to determine the superiority of the treatment protocol over alternative implant rehabilitation approaches. Patient-reported outcomes were based on subjective ratings, which may have been influenced by individual expectations and perceptions. Despite these limitations, the study provides useful clinical insight into implant stability, peri-implant health, radiographic outcomes, prosthetic performance, and patient satisfaction over the observation period.

11. Conclusion

The present study demonstrated favourable clinical, radiographic, prosthetic, and patient-reported outcomes following implant-supported rehabilitation over a 12-month observation period. Most patients exhibited stable implants with minimal mobility, accompanied by progressive improvements in peri-implant plaque accumulation and gingival health. MBL remained within acceptable limits in the majority of cases, while satisfactory cortical anchorage and the absence of peri-implant radiolucency were observed in most patients. Prosthetic complications were relatively uncommon, and implant survival and composite functional success rates were encouraging. Patient satisfaction was consistently high across the evaluated domains, including comfort, esthetics, chewing efficiency, and overall satisfaction. These findings suggest that implant-supported rehabilitation can provide predictable functional and esthetic benefits when appropriate case selection, treatment planning, clinical execution, and follow-up are maintained. However, further multicentre studies with larger sample sizes, comparative designs, and longer follow-up periods are required to validate these outcomes and establish long-term clinical predictability.

- **Conflicts of Interest:** Nil
- **Financial Support:** None

References

1. Sailer I, Barbato L, Mojon P, Pagliaro U, Serni L, Karasan D, Cairo F. Single and partial tooth replacement with fixed dental prostheses supported by dental implants: A systematic review of outcomes and outcome measures used in clinical trials in the last 10 years. J Clin Periodontol. 2023 May;50 Suppl 25:22-37. doi: 10.1111/jcpe.13612. Epub 2022 Jun 5. PMID: 35246885.
2. Papaspyridakos P, Chen CJ, Chuang SK, Weber HP, Gallucci GO. A systematic review of biologic and technical complications with fixed implant rehabilitations for edentulous patients. Int J Oral Maxillofac Implants. 2012 Jan-Feb;27(1):102-10. PMID: 22299086.
3. Satpathy A, Grover V, Kumar A, Jain A, Gopalakrishnan D, Grover HS, Kolte A, Melath A, Khatri M, Dani N, Thakur R, Tiwari V, Yadav VS, Thomas B, Chahal GS, Bhasin MT, Pandit N, Lawande SA, Manjunath RGS, Sachdeva S, Bhardwaj A, Pradeep AR, Nichani AS, Singh B, Ganesh PR, Deshpande NC, Reddy SSP, Raj SC. Indian Society of Periodontology Good Clinical Practice Recommendations for Peri-implant Care. J Indian Soc Periodontol. 2024 Jan-Feb;28(1):6-31. doi: 10.4103/jisp.jisp_124_24. Epub 2024 Jun 4. PMID: 38988964; PMCID: PMC11232813.
4. Lin GH, Lee E, Barootchi S, et al. The influence of prosthetic designs on peri-implant bone loss: An AO/AAP systematic review and meta-analysis. J Periodontol. 2025; 96: 634–651. https://doi.org/10.1002/JPER.24-0144
5. Verma A, Singh SV, Arya D, Shivakumar S, Chand P. Mechanical failures of dental implants and supported prostheses: A systematic review. J Oral Biol Craniofac Res. 2023 Mar-Apr;13(2):306-314. doi: 10.1016/j.jobcr.2023.02.009. Epub 2023 Mar 3. PMID: 36923071; PMCID: PMC10009286.
6. Reissmann DR, Dard M, Lamprecht R, Struppek J, Heydecke G. Oral health-related quality of life in subjects with implant-supported prostheses: A systematic review. J Dent. 2017 Oct;65:22-40. doi: 10.1016/j.jdent.2017.08.003. Epub 2017 Aug 5. PMID: 28789860.
7. Duong HY, Roccuzzo A, Stähli A, Salvi GE, Lang NP, Sculean A. Oral health-related quality of life of patients rehabilitated with fixed and removable implant-supported dental prostheses. Periodontol 2000. 2022 Feb;88(1):201-237. doi: 10.1111/prd.12419. PMID: 35103325; PMCID: PMC9304161.

8. French D, Ofec R, Levin L. Long term clinical performance of 10 871 dental implants with up to 22 years of follow-up: A cohort study in 4247 patients. Clin Implant Dent Relat Res. 2021 Jun;23(3):289-297. doi: 10.1111/cid.12994. Epub 2021 Mar 25. PMID: 33768695; PMCID: PMC8359846.
9. Ramanauskaite A, Becker K, Wolfart S, Lukman F, Schwarz F. Efficacy of rehabilitation with different approaches of implant-supported full-arch prosthetic designs: A systematic review. J Clin Periodontol. 2022 Jun;49 Suppl 24:272-290. doi: 10.1111/jcpe.13540. Epub 2021 Nov 10. PMID: 34761399.
10. Gaddale R, Mishra SK, Chowdhary R. Complications of screw- and cement-retained implant-supported full-arch restorations: a systematic review and meta-analysis. Int J Oral Implantol (Berl). 2020;13(1):11-40. PMID: 32186285.
11. Gallardo YNR, da Silva-Olivio IR, Gonzaga L, Sesma N, Martin W. A Systematic Review of Clinical Outcomes on Patients Rehabilitated with Complete-Arch Fixed Implant-Supported Prostheses According to the Time of Loading. J Prosthodont. 2019 Dec;28(9):958-968. doi: 10.1111/jopr.13104. Epub 2019 Oct 18. PMID: 31433096.
12. de Luna Gomes JM, Lemos CAA, Santiago Junior JF, de Moraes SLD, Goiato MC, Pellizzer EP. Optimal number of implants for complete-arch implant-supported prostheses with a follow-up of at least 5 years: A systematic review and meta-analysis. J Prosthet Dent. 2019 May;121(5):766-774.e3. doi: 10.1016/j.prosdent.2018.06.001. Epub 2018 Dec 4. PMID: 30527569.
13. Del Fabbro M, Pozzi A, Romeo D, de Araújo Nobre M, Agliardi E. Outcomes of Fixed Full-Arch Rehabilitations Supported by Tilted and Axially Placed Implants: A Systematic Review and Meta-Analysis. Int J Oral Maxillofac Implants. 2022 Sep-Oct;37(5):1003-1025. doi: 10.11607/jomi.9710. PMID: 36170316.
14. Monteiro CGJ, de Oliveira Silva AM, de Almeida DCF, Velloso G, da Silva AMP, Filho WPA, Moraschini V. Clinical outcomes of zirconia implants supporting multi-unit and complete arch prostheses: A systematic review and meta-analysis. J Prosthet Dent. 2025 Nov;134(5):1631.e1-1631.e8. doi: 10.1016/j.prosdent.2025.07.020. Epub 2025 Aug 7. PMID: 40781015.
15. Francisco H, Pinto C, Romito GA, Panutti CM, Marques D, Caramês J. Patient- and Clinician-Reported Outcomes and Outcome Measures Evaluating Maxillary Full Arch Fixed Prostheses Supported by Different Numbers of Implants: A Systematic Review. Clin Oral Implants Res. 2026 Feb;37 Suppl 30(Suppl 30):S273-S301. doi: 10.1111/clr.70020. PMID: 41732069; PMCID: PMC12930126.