Research Article

Management Of Complicated Crown Fracture Through Partial Pulpotomy And Tooth Fragment Reattachment: a Case Report.

Ritika Jain[1], Niraj Kinariwala[2], Harsh Patel[3], Fenny Patel[4], Vacha Patel[5], Hetarth Patel[6]

[1]Post Graduate Student,Department of Conservative Dentistry and Endodontics, Karnavati School of Dentistry, Karnavati University, Mail id: ritikajain546@gmail.com
[2]Professor, Department of Conservative Dentistry and Endodontics, Karnavati School of Dentistry, Karnavati University, Mail id: nirajkinariwala@karnavatiuniversity.edu.in
[3]Final Year Student, Karnavati School of Dentistry, Karnavati University, Mail id: harshpatel7291@gmail.com
[4]Final Year Student, Karnavati School of Dentistry, Karnavati University, Mail id: fennypatel9898@gmail.com
[5]Final Year Student, Karnavati School of Dentistry, Karnavati University, Mail id: vachapatel307@gmail.com
[6]Final Year Student, Karnavati School of Dentistry, Karnavati University, Mail id: hetarthpatel1109@gmail.com

Abstract

Background**:** Complicated crown fractures involving traumatic pulp exposure in permanent anterior teeth present both biological and restorative challenges, particularly in young patients. Vital pulp therapy combined with tooth fragment reattachment can preserve pulp vitality while restoring the tooth's original anatomy and appearance.

Case Presentation: A 15-year-old female presented with a complicated crown fracture of the maxillary left central incisor (tooth 21), accompanied by traumatic pulp exposure. The patient presented 30 minutes after the injury with the fractured fragment stored dry in a plastic container. Following clinical and radiographic assessment, the tooth was diagnosed with reversible pulpitis and symptomatic apical periodontitis associated with a complicated crown fracture and traumatic pulp exposure. Partial pulpotomy was performed under local anaesthesia using 2% lignocaine. Approximately 2 mm of coronal pulp tissue was removed, and haemostasis was achieved within 3 minutes using a cotton pellet moistened with 2.5% sodium hypochlorite. Biodentine was placed directly over the remaining pulp tissue and allowed to set. The fractured fragment was rehydrated in normal saline for 30 minutes before reattachment. An external bevel was prepared on both the tooth remnant and the fragment, while a 2 mm internal dentinal groove was prepared on the palatal surface of the fragment. Following air-particle abrasion and adhesive surface treatment, the fragment was reattached using RelyX Ultimate dual-cure resin cement. Clinical and radiographic evaluations at 3 and 6 months demonstrated an asymptomatic tooth, positive responses to cold and electric pulp sensibility testing, negative percussion, normal radiographic findings, and no visible discoloration.

Conclusion: Within the limitations of a single case and six months of follow-up, the combined approach demonstrated a favourable clinical and radiographic outcome. Biodentine-assisted partial pulpotomy, followed by adhesive fragment reattachment, may offer a conservative treatment option for selected complicated crown fractures when preservation of pulp vitality and natural tooth structure is feasible.

Keywords: Complicated crown fracture, Tooth fragment reattachment, Biodentine, Partial pulpotomy, Vital pulp therapy

1. Introduction

Traumatic dental injuries involving the permanent anterior teeth are common in children and adolescents and may have significant functional, biological, and aesthetic consequences. Complicated crown fractures, characterised by fractures involving enamel and dentin with pulp exposure, require prompt assessment and appropriate management to preserve the vitality of the pulp while restoring the structural integrity and appearance of the affected tooth. Treatment planning should consider the extent of the fracture, the condition of the exposed pulp, the stage of root development, the time elapsed since injury, and the availability of the fractured fragment [1,2].

Vital pulp therapy (VPT) is an important treatment strategy for permanent teeth with traumatic pulp exposure. Among the available procedures, partial pulpotomy involves the removal of a limited portion of superficially inflamed or contaminated coronal pulp tissue, followed by the placement of a suitable bioactive material over the remaining pulp. This approach aims to preserve viable pulp tissue and maintain its biological functions. The International Association of Dental Traumatology (IADT) recommends conservative pulp treatment, including partial pulpotomy, for appropriate cases of complicated crown fracture in permanent teeth. The European Society of Endodontology also recognises partial pulpotomy as a preferred approach for many traumatic pulp exposures, particularly when the exposure is extensive or treatment is not undertaken immediately after the injury [1,2].

Evidence supporting vital pulp therapy following traumatic pulp exposure has demonstrated encouraging clinical and radiographic outcomes. A systematic review by Matoug-Elwerfelli and colleagues reported that partial

pulpotomy was the most frequently investigated vital pulp treatment procedure among the included studies, with reported success rates ranging from 82.9% to 100%. However, the authors highlighted limitations in the available evidence, including variability in study quality and the relatively small number of studies evaluating newer bioactive materials [3]. Calcium silicate-based materials, including Biodentine, have attracted interest in vital pulp therapy because of their bioactivity, ability to support mineralised tissue formation, and potential suitability for use in aesthetic areas. Biodentine is also a relevant material in anterior teeth, where maintaining crown colour is an important restorative consideration [3].

When the fractured crown fragment is available, adhesive fragment reattachment offers a conservative alternative to conventional restorative procedures. Reattachment can preserve the original tooth morphology, surface texture, translucency, and incisal anatomy while reducing the need for extensive removal of sound tooth structure. The IADT guidelines recommend considering reattachment of an available fragment following appropriate management of the exposed pulp [1]. Nevertheless, the clinical performance of the reattached fragment depends on several factors, including the condition and handling of the fragment, rehydration before bonding, adaptation of the fractured surfaces, surface preparation, adhesive protocol, and restorative material selection.

Combining partial pulpotomy with adhesive fragment reattachment therefore addresses both major objectives in the management of complicated crown fractures: preservation of pulp vitality and restoration of the natural crown form. This case report describes the management of a complicated crown fracture involving the maxillary left central incisor of a 15-year-old female using partial pulpotomy with Biodentine, followed by adhesive tooth fragment reattachment. The clinical and radiographic findings at 3- and 6-month follow-up are presented to document the short-term outcome of this combined approach.

2. Case Presentation

Patient Information and History

A 15-year-old female patient presented to the Department of Conservative Dentistry and Endodontics, Karnavati School of Dentistry, Karnavati University, accompanied by her mother, with a complaint of trauma involving the maxillary anterior region. The patient reported sustaining the injury approximately 30 minutes before presentation. The fractured tooth fragment had been retrieved by her mother from the accident site and transported to the clinic in a plastic container without any storage medium. No associated soft-tissue injuries were reported or observed.

Clinical and Radiographic Examination

Clinical examination revealed a complicated crown fracture involving the maxillary left central incisor (tooth 21), with exposure of the underlying pulp tissue. The fractured fragment was available and appeared suitable for reattachment. Preoperative clinical photographs were obtained to document the extent of the fracture and the condition of the remaining tooth structure (Figure 1).

Radiographic examination revealed a fracture involving the crown of tooth 21, with the fracture line extending through the region of the pulp horns. Slight widening of the periodontal ligament space was also observed (Figure 2).

Pulp sensibility testing elicited a positive response to cold testing, which was brief and non-lingering. Percussion testing elicited a positive response. Based on the clinical and radiographic findings, tooth 21 was diagnosed with reversible pulpitis and symptomatic apical periodontitis secondary to a complicated crown fracture with traumatic pulp exposure.



Preoperative Clinical Appearance of the Complicate Crown Fracture involving Tooth i.r.t. 21



Preoperative periapical radiograph demonstrating the crown fracture involving tooth 21

Treatment Planning

Considering the patient's young age, the availability of the fractured fragment, and the possibility of preserving the remaining vital pulp tissue, a conservative treatment approach was selected. The treatment plan involved partial pulpotomy using Biodentine as the pulp-capping material, followed by adhesive reattachment of the original tooth fragment.

Treatment Procedure

The fractured fragment was first repositioned on the remaining tooth structure to assess its adaptation and confirm the possibility of accurate reattachment. The fragment was subsequently immersed in normal saline for 30 minutes to facilitate rehydration (Figures 3 and 4).



Trial repositioning of the fractured fragment to evaluate adaptation and restoration of the original crown contour.



Rehydration of the retrieved tooth fragment in normal saline for 30 minutes before reattachment.

The procedure was performed under local anaesthesia using 2% lignocaine (XICAINE). Following rubber dam isolation, approximately 2 mm of the exposed coronal pulp tissue was removed using a sterile bur. Haemostasis was achieved within 3 minutes using a sterile cotton pellet moistened with 2.5% sodium hypochlorite (NaOCl). The appearance of healthy pulp tissue and achievement of haemostasis were considered suitable for proceeding with vital pulp therapy (Figures 5 and 6).



Rubberdam Isolation of tooth 21

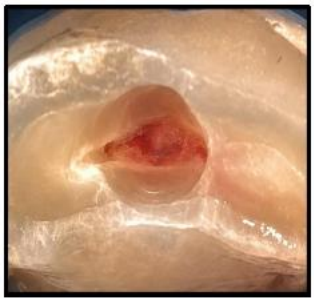

Achievement of haemostasis following removal of approximately 2 mm of coronal pulp tissue using 2.5% sodium hypochlorite.

Biodentine was placed directly over the remaining pulp tissue in an approximately 2-mm-thick layer and allowed to set before proceeding with the restorative phase (Figure 7).



Placement of Biodentine directly over the remaining pulp tissue.

For fragment reattachment, an external bevel was prepared on both the remaining tooth structure and the fractured fragment. Additionally, a 2-mm internal dentinal groove was prepared exclusively on the palatal surface of the fragment to facilitate mechanical interlocking and improve the retention of the reattached fragment (Figure 8).



Preparation of the external bevel on the tooth remnant and fragment

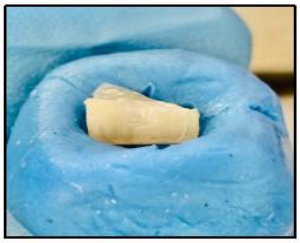

Preparation of internal dentinal groove on the palatal surface of the fragment.

Air-particle abrasion was performed on the bonding surfaces of the tooth remnant and the fragment using 50-µm aluminium oxide particles at a pressure of 40–60 psi. The adjacent teeth were protected using polytetrafluoroethylene (PTFE) tape during this procedure (Figure 9).

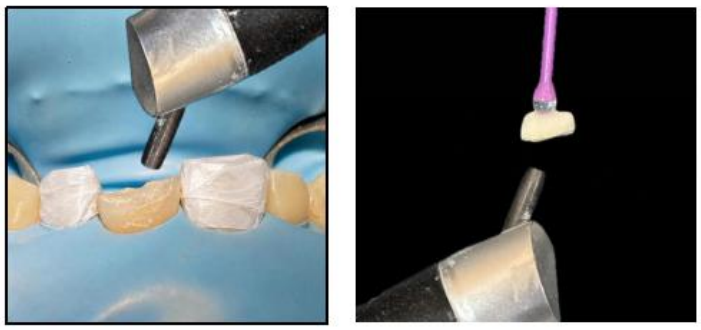

Air-particle abrasion of the bonding surfaces using 50-µm aluminium oxide particles.

The bonding surfaces were subsequently treated using 37% phosphoric acid where indicated by the adhesive protocol. Scotchbond Universal adhesive (3M) was applied using a self-etch approach, actively applied for 20 seconds, gently air-dried, and light-cured according to the manufacturer's instructions (Figure 10).

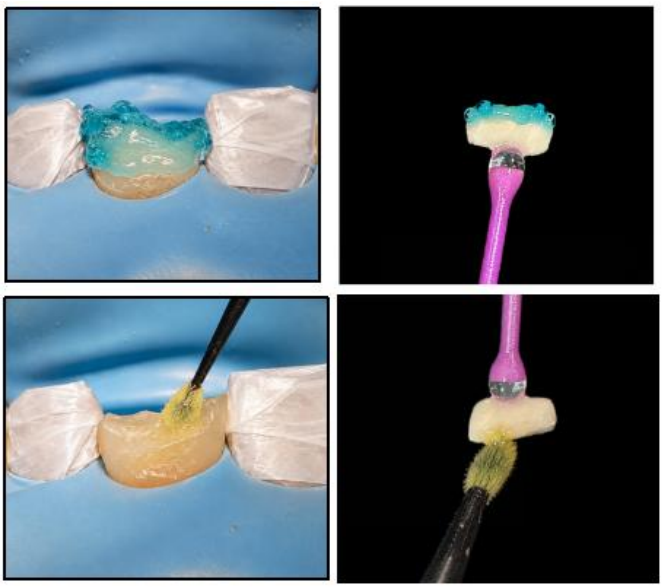

Adhesive surface treatment using phosphoric acid etching where indicated, followed by application of Scotchbond Universal adhesive.

RelyX Ultimate dual-cure adhesive resin cement was used for fragment reattachment. The cement was applied to the prepared bonding surfaces, and the fragment was carefully repositioned to achieve accurate adaptation with the remaining tooth structure. Excess cement was removed, and polymerisation was completed using both light- and chemical-curing mechanisms, following the manufacturer's protocol (Figure 11)

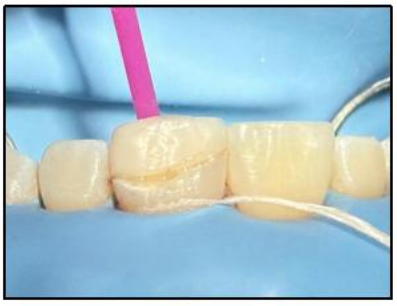

Adhesive reattachment of the fractured fragment using RelyX Ultimate dual-cure resin cement.

Follow-up and Outcome

Clinical and radiographic evaluations were performed immediately after treatment and at 3- and 6-month intervals. The immediate postoperative clinical examination demonstrated satisfactory adaptation of the reattached fragment and restoration of the original crown contour (Figure 12).

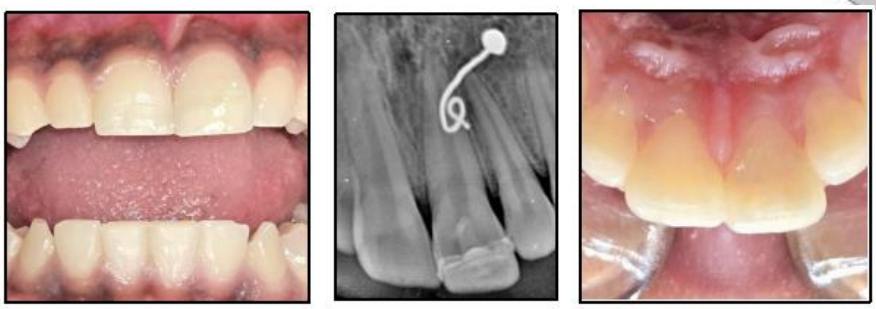

Immediate postoperative radiographic and clinical appearance following partial pulpotomy and fragment reattachment.

At both follow-up visits, the patient remained asymptomatic. The treated tooth demonstrated positive responses to cold testing and electric pulp testing, with no tenderness to percussion. Radiographic examination revealed normal periapical findings, with no evidence of pathological changes. No visible crown discoloration was observed during the follow-up period (Figure 13).

The clinical and radiographic findings at the 6-month evaluation indicated a favourable short-term outcome following partial pulpotomy and adhesive fragment reattachment.



Radiographic follow-up at 3 and 6 months demonstrating maintenance of the restored crown, absence of symptoms, and favourable periapical findings.

3. Discussion

Complicated crown fractures involving traumatic pulp exposure represent a clinical challenge because treatment must address both the biological consequences of the injury and the restoration of the fractured crown. In young permanent teeth, preservation of the pulp is particularly important because it maintains the biological functions of the tooth and, in immature teeth, supports continued root development. The International Association of Dental Traumatology (IADT) guidelines recommend considering conservative pulp treatment and reattachment of the original fragment when appropriate [1]. In the present case, a combined approach involving partial pulpotomy with Biodentine followed by adhesive fragment reattachment was selected to preserve the remaining pulp tissue and restore the natural crown anatomy of the maxillary left central incisor.

Rationale for partial pulpotomy following traumatic pulp exposure

The choice of vital pulp therapy depends on several factors, including the extent of pulp exposure, the time elapsed since trauma, the clinical condition of the exposed pulp, and the ability to achieve haemostasis. Partial pulpotomy involves the removal of a limited portion of superficially affected coronal pulp tissue, followed by placement of a suitable bioactive material over the remaining pulp. This approach allows the preservation of healthy pulp tissue while removing tissue that may have been affected by contamination and inflammation following trauma.

Evidence supporting pulpotomy for complicated crown fractures has been reported in systematic reviews. Donnelly et al. evaluated pulpotomy as a treatment for complicated crown fractures in permanent teeth and highlighted its role as a conservative treatment option [2]. Similarly, Matoug-Elwerfelli et al. reviewed vital pulp treatment in traumatised permanent teeth and reported favourable outcomes, while acknowledging limitations in the quality and consistency of the available evidence [3]. A separate systematic review and meta-analysis by Matoug-Elwerfelli et al. specifically evaluated partial pulpotomy in traumatised permanent anterior teeth and reported an overall pooled success estimate of 89% [4]. These findings support the consideration of partial pulpotomy as a definitive treatment option in appropriately selected cases.

In the present case, approximately 2 mm of coronal pulp tissue was removed, and haemostasis was achieved within 3 minutes using 2.5% sodium hypochlorite. The appearance of the remaining pulp tissue and the ability to achieve haemostasis supported proceeding with vital pulp therapy. However, haemostasis alone should not be regarded as definitive evidence of pulp health; it must be interpreted alongside the clinical findings and subsequent follow-up observations.

Selection of Biodentine as the pulp-capping material

The choice of pulp-capping material is an important consideration in vital pulp therapy. Calcium silicate-based materials, including Biodentine and mineral trioxide aggregate (MTA), have been investigated because of their biocompatibility and potential to support reparative dentin formation. In a clinical study involving traumatised permanent teeth with complicated crown fractures, Haikal et al. evaluated pulpotomies performed using Biodentine and reported favourable clinical outcomes [5].

Abuelniel et al. compared MTA and Biodentine in a randomised clinical trial involving traumatised immature permanent anterior teeth. Both materials demonstrated comparable clinical and radiographic outcomes, although discoloration was more prevalent in the MTA group [6]. These findings are particularly relevant to anterior teeth, where the appearance of the restored crown is an important treatment consideration. A systematic review examining the discoloration potential of Biodentine also emphasised the importance of considering the material's colour stability when it is used in aesthetically sensitive areas [7].

In the present case, Biodentine was placed directly over the remaining pulp tissue following haemostasis. At the 3- and 6-month follow-up examinations, the tooth remained asymptomatic and no visible crown discoloration was observed. These findings are consistent with a favourable short-term clinical outcome. Nevertheless, the absence of visible discoloration in a single case does not establish that Biodentine is free from discoloration potential, and longer follow-up is required to evaluate its long-term aesthetic performance.

Fragment rehydration before reattachment

When the original fractured fragment is available and suitable for bonding, reattachment offers a conservative alternative to conventional restorative procedures. This technique preserves the natural morphology, surface texture, translucency, and incisal anatomy of the tooth while limiting additional removal of sound tooth structure. Garcia et al., in a systematic review of tooth fragment reattachment techniques, highlighted the variety of techniques described in the literature and the absence of conclusive evidence establishing a universally superior preparation method [8]. Yilmaz et al. also investigated fragment reattachment through clinical and laboratory studies, demonstrating the relevance of fragment management and adhesive procedures to treatment outcomes [9].

In the present case, the fragment was retrieved shortly after the injury but had been stored dry in a plastic container. Dehydration can alter the optical appearance of a fragment and may influence the bond strength achieved during reattachment. Rehydration before bonding is therefore an important consideration when a fragment has been

stored dry. Shirani et al. investigated the influence of hydration and dehydration periods on the bonding of crown fragments and highlighted the relevance of fragment hydration to reattachment procedures [10]. Capp et al. also described reattachment techniques involving rehydrated dental fragments [11].
Accordingly, the fragment in the present case was immersed in normal saline for 30 minutes before reattachment. This step was intended to facilitate rehydration before the adhesive procedure. Although satisfactory aesthetic integration was observed clinically, the contribution of this specific rehydration period to the final bond strength cannot be established from the outcome of a single case.

Influence of preparation design on fragment retention

The preparation design selected for fragment reattachment can influence the available bonding surface and the mechanical behaviour of the restored tooth. Different approaches, including simple reattachment, external bevel preparation, internal dentinal grooves, and combined techniques, have been investigated to improve fracture resistance.
Demarco et al. examined the influence of bevel preparation and adhesive materials on the fracture resistance of reattached coronal fragments [12]. Pusman et al. compared different preparation techniques and adhesive materials, including internal dentinal groove and overcontour approaches [13]. Stellini et al. also evaluated the fracture strength of reattached fragments using different preparation designs [14]. More recently, Chandran et al. compared simple, bevel, and internal groove preparation designs in an in vitro study, further demonstrating the clinical interest in modifying the fracture interface to improve the mechanical performance of reattached fragments [15].
In the present case, an external bevel was prepared on both the remaining tooth structure and the fractured fragment. Additionally, a 2-mm internal dentinal groove was prepared on the palatal surface of the fragment. This combined preparation was intended to increase the available bonding area and provide additional mechanical interlocking while preserving the natural facial surface of the anterior tooth. However, the effectiveness of this particular combination cannot be quantified from the present case because no comparative fracture resistance testing was performed. Furthermore, laboratory findings concerning fracture resistance cannot be directly translated into long-term clinical survival without supporting clinical evidence.

Adhesive surface treatment and fragment reattachment

The performance of a reattached fragment also depends on the condition of the bonding surfaces and the adhesive protocol. In the present case, air-particle abrasion was performed on the bonding surfaces using 50-µm aluminium oxide particles at a pressure of 40–60 psi. The surfaces were subsequently treated with phosphoric acid where indicated by the adhesive protocol, followed by application of Scotchbond Universal adhesive. RelyX Ultimate dual-cure adhesive resin cement was used to reattach the fragment.
The purpose of surface conditioning was to prepare the bonding interfaces and facilitate effective adhesion between the fragment and the remaining tooth structure. The use of an adhesive resin cement was intended to provide intimate adaptation at the fracture interface. The dual-cure mechanism of the selected cement also permitted polymerisation through both light-activated and chemical-curing mechanisms, which may be beneficial when light accessibility is limited. Nevertheless, the present case does not allow the individual contribution of air-particle abrasion, the adhesive system, or the resin cement to be isolated.
The literature on fragment reattachment indicates that preparation design and adhesive material selection should be considered together rather than as independent factors [8,12,13]. Therefore, the present technique should be interpreted as a combined restorative protocol rather than evidence that any single component is superior to alternative approaches.

4. Clinical and radiographic outcome

At the 3- and 6-month follow-up examinations, the patient remained asymptomatic, and the treated tooth demonstrated positive responses to cold and electric pulp sensibility testing. There was no tenderness to percussion,

and radiographic examination revealed no evidence of pathological periapical changes. No visible crown discoloration was observed during the follow-up period.

Pulp sensibility tests evaluate neural responsiveness rather than pulpal blood supply. Their interpretation after traumatic dental injuries requires caution because temporary alterations in neural responses can occur following trauma. Bastos et al. investigated pulpal responses to sensibility tests after traumatic dental injuries and highlighted the limitations of these tests when evaluating pulp status [16]. The IADT guidelines similarly recommend serial clinical, radiographic, and sensibility assessments during follow-up [1]. Consequently, the positive responses observed in the present case, together with the absence of symptoms and pathological radiographic findings, are consistent with a favourable short-term outcome but do not independently establish the long-term biological success of the treatment.

An important feature of this case is the integration of pulp-preserving treatment with restoration using the original tooth fragment. The biological phase addressed the traumatic pulp exposure, while the restorative phase aimed to re-establish the natural crown anatomy with minimal additional loss of tooth structure. This approach is consistent with the conservative principles underlying contemporary management of traumatic dental injuries [1,3,8].

5. Limitations and clinical implications

The principal limitation of this report is that it describes a single case with a follow-up period of six months. Although the clinical and radiographic findings were favourable, the duration of observation does not establish long-term pulp survival, fracture resistance, or the durability of the adhesive interface. No quantitative evaluation of bond strength or fracture resistance was performed, and the separate contributions of the external bevel, internal groove, air-particle abrasion, adhesive, and resin cement cannot be determined.

Furthermore, the results should not be interpreted as evidence that the combined preparation design is superior to simpler reattachment techniques. The literature remains heterogeneous with respect to preparation designs, adhesive materials, and outcome assessment [8,13,15]. Longer clinical follow-up and comparative studies are required to determine whether the combined approach offers a meaningful advantage in clinical survival.

Within these limitations, the present case demonstrates that Biodentine-assisted partial pulpotomy followed by adhesive fragment reattachment can be considered a conservative treatment option for selected complicated crown fractures. The favourable short-term findings support the feasibility of combining biological pulp preservation with restoration of the original crown morphology. However, the long-term prognosis remains dependent on continued clinical and radiographic monitoring.

6. Conclusion

The present case demonstrates a favourable short-term clinical and radiographic outcome following partial pulpotomy using Biodentine and adhesive reattachment of the original tooth fragment in a young patient with a complicated crown fracture. The combined approach preserved the natural crown anatomy, maintained positive pulp sensibility responses, and achieved satisfactory aesthetic integration without visible discoloration during six months of follow-up.

This technique may be considered a conservative treatment option for appropriately selected traumatic crown fractures when pulp preservation and fragment reattachment are feasible. Nevertheless, longer follow-up and further clinical studies are necessary to evaluate the long-term biological and restorative outcomes and to establish the comparative effectiveness of different fragment preparation designs.

7. References:

1. Bourguignon C, Cohenca N, Lauridsen E, Flores MT, O'Connell AC, Day PF, et al. International Association of Dental Traumatology guidelines for the management of traumatic dental injuries: 1. Fractures and luxations. Dent Traumatol. 2020;36(4):314–330.

2. Donnelly A, Foschi F, McCabe P, Duncan HF. Pulpotomy for treatment of complicated crown fractures in permanent teeth: A systematic review. Int Endod J. 2022;55(4):290–311.
3. Matoug-Elwerfelli M, ElSheshtawy AS, Duggal M, Tong HJ, Nazzal H. Vital pulp treatment for traumatized permanent teeth: A systematic review. Int Endod J. 2022;55(6):613–629.
4. Camoni, N., Cagetti, M. G., Cirio, S., Esteves-Oliveira, M., & Campus, G. (2023). Partial Pulpotomy in Young Permanent Teeth: A Systematic Review and Meta-Analysis. Children (Basel, Switzerland), 10(9), 1447. https://doi.org/10.3390/children10091447
5. Haikal L, Dos Santos BF, Vu DD, Braniste M, Dabbagh B. Biodentine pulpotomies on permanent traumatized teeth with complicated crown fractures. J Endod. 2020;46(9):1204–1209.
6. Abuelniel GM, Duggal MS, Kabel N. A comparison of MTA and Biodentine as medicaments for pulpotomy in traumatized anterior immature permanent teeth: A randomized clinical trial. Dent Traumatol. 2020;36(4):400–410.
7. Discoloration potential of Biodentine: A Systematic Review. Slaboseviciute, M., Vasiliauskaite, N., Drukteinis, S., Martens, L., & Rajasekharan, S. (2021). Discoloration Potential of Biodentine: A Systematic Review. Materials (Basel, Switzerland), 14(22), 6861. https://doi.org/10.3390/ma14226861
8. Garcia FCP, Poubel DLN, Almeida JCF, Toledo IP, Poi WR, Guerra ENS, et al. Tooth fragment reattachment techniques—A systematic review. Dent Traumatol. 2018;34(3):135–143.
9. Yilmaz Y, Guler C, Sahin H, Eyuboglu O. Evaluation of tooth-fragment reattachment: A clinical and laboratory study. Dent Traumatol. 2010;26(4):308–314.
10. Shirani F, Malekipour MR, Sakhaei Manesh V, Aghaei F. Hydration and dehydration periods of crown fragments prior to reattachment. Oper Dent. 2012;37(5):501–508.
11. Capp CI, Roda MI, Tamaki R, Castanho GM, Camargo MA, de Cara AA. Reattachment of rehydrated dental fragment using two techniques. Dent Traumatol. 2009;25(1):95–99.
12. Demarco FF, Fay RM, Pinzon LM, Powers JM. Fracture resistance of re-attached coronal fragments—influence of different adhesive materials and bevel preparation. Dent Traumatol. 2004;20(3):157–163.
13. Pusman E, Cehreli ZC, Altay N, Unver B, Saracbasi O, Ozgun G. Fracture resistance of tooth fragment reattachment: Effects of different preparation techniques and adhesive materials. Dent Traumatol. 2010;26(1):9–15.
14. Stellini E, Stomaci D, Stomaci M, Petrone N, Favero L. Fracture strength of tooth fragment reattachments with postpone bevel and overcontour reconstruction. Dent Traumatol. 2008;24(3):283–288.
15. Chandran R, Rayar S, Ravi AB, Haridas K. Comparative evaluation of fracture resistance of incisor fragments using simple, bevel, internal groove preparation designs and reattached with nanocomposites: An in vitro study. J Pharm Bioallied Sci. 2020;12(Suppl 1):S373–S377.
16. Bastos JV, Goulart EMA, Côrtes MIS. Pulpal response to sensibility tests after traumatic dental injuries in permanent teeth. Dent Traumatol. 2014;30(3):188–192.
17. Lise DPL, Cardoso Vieira LC, Araújo É, Lopes GC. Tooth fragment reattachment: The natural restoration. Oper Dent. 2012;37(6):584–590.
18. Duncan HF, Galler KM, Tomson PL, Simon S, El-Karim I, Kundzina R, et al. European Society of Endodontology position statement: Management of deep caries and the exposed pulp. Int Endod J. 2019;52(7):923–934.